

THE EFFECT OF TOPICAL MACROPHAGE-REGULATOR ON CHRONIC BURN WOUND: A CASE REPORT

Kwan-Lok Benjamin Ng¹, I-Chien Chen⁴, Bei-Ling Chen, BSN,RN^{2,5}, Shu-Hung Huang, M.D., Ph.D.^{2,3}

1. Department of Surgery, Kaohsiung Medical University Hospital, Kaohsiung Medical University, Kaohsiung City, Taiwan

2. Division of Plastic Surgery, Department of Surgery, Kaohsiung Municipal Siaoang Hospital, Kaohsiung City, Taiwan

3. Faculty of Medicine, College of Medicine, Kaohsiung Medical University, Kaohsiung City, Taiwan

4. Division of Performance Management, Kaohsiung Medical University Hospital, Kaohsiung City, Taiwan

5. Nurse Practitioner, Division of Plastic Surgery, Department of Nursing, Kaohsiung Medical University Hospital, Kaohsiung Medical University, Kaohsiung, Taiwan

+ Introduction

Flame burn victims are forced to live a life of long-lasting morbidity. Delayed wound healing affect patients not only physically, but mentally. Various treatments are used to treat chronic wounds but the best treatment is still debatable. Topical macrophage-regulator is a cream with the proprietary ingredients to manage chronic wounds through macrophage subtypes regulation and betterment of anti-inflammation. Numerous studies reported the cream's good healing outcomes on diabetic wounds but currently no study was reported to investigate its effect on burn wounds. This case report aims to present the effect of topical macrophage-regulator on chronic burn wound.

+ Methods

A 26-year-old female burn victim presented to our Plastic Surgery clinic with the complaint of a chronic wound over her left post auricular area. Tracing back her history, she was a Chemistry teacher who experienced a 13% TBSA (Total Body Surface Area) second to third degree fire related skin burns in the face, bilateral upper limbs and anterior chest during an accident in the experiment class. She was admitted in another burn centre where first aid and management were given. She visited our facility due to a chronic non-healing skin wound over her post auricular area. During physical examination, a 2nd degree superficial burn wound was noted behind her left ear with redness and blister formation. We provided the wound with moisturizer and wound dressing with Silicone-Faced Dressing. Despite long-term care for weeks, the wound healing progress was slow with very limited improvement. Regarding her skin wound, topical macrophage-regulator was applied twice daily after well sterilization. First, the burn wound was cleansed by normal saline solution. Then, topical macrophage-regulator is applied to most of the wound. The patient changed wound dressing at home by herself for 3 weeks and the condition of the wound is recorded by a camera.

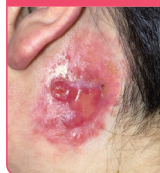+ Discussion

Topical macrophage-regulator is an effective and affordable alternative to chronic burn wounds. To our best knowledge, this is one of the first case reports of this topical cream's effect on burn injuries with satisfactory outcome. For patients presented with a chronic burn wound, topical macrophage-regulator may be considered.

+ Results

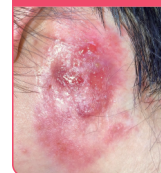After the treatment with topical macrophage-regulator, the healing process started with the decrease in serous secretion and followed by formation of granulation tissue and epithelialization of the wound. Three weeks after topical treatment of macrophage-regulator initiation, the wound healed uneventfully with acceptable aesthetic outcome.

Fig 1



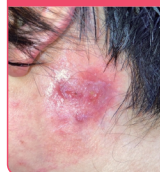
A 2nd degree superficial burn wound with poor healing for 3 months behind her left ear.

Fig 2



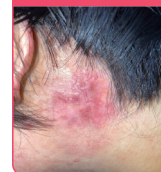Six days after treatment, show decreased serous secretion with no sign of severity progression.

Fig 3



Ten days after topical macrophage-regulator usage showing formation of granulation tissue and epithelialization of the wound.

Fig 4



Wound healed uneventfully with acceptable aesthetic outcome at 18 days of topical macrophage-regulator use.

References

1. Robert RB, Elizabeth LW, Charles GT et al. Epidemiology of flame burn injuries. *Burns* 1984; 11(1-10)
2. G Bohn, B Liden, G Schultz et al. *Adv Wound Care* (New Rochelle); 2016 Jan 1;5(1):1-10.
3. Mosser DM, Edwards JP. Exploring the full spectrum of macrophage activation [research support, N.I.H., extramural review]. *Nat Rev Immunol.* 2008;8(12):958-969.
4. Novak ML, Koh TJ. Macrophage phenotypes during tissue repair. *J Leukoc Biol.* 2013;93(6):875-881.
5. CW Lin, CC Chen, WY Huang et al. Restoring Prohealing/Remodeling-Associated M2a/c Macrophages Using ON101 Accelerates Diabetic Wound Healing. *JID Innov.* 2022 Jun 2;2(5):100138.
6. Peck, M.D. (2011) Epidemiology of Burns throughout the World. Part I: Distribution and Risk Factors. *Burns*, 37, 1087-1100.