

Breaking the Cycle: Life Saving ICD in Methadone-Induced Torsades de Pointes

Tara Ward MSN, RN, AGACNP-BC | Haley Briggs PA-C | Elizabeth McWilliams PA-C | Catherine Callister, MD



University of Colorado
Anschutz Medical Campus

LEARNING OBJECTIVES

- ✓ Analyze the incidence of and risk factors for QT prolongation associated with methadone therapy in patients with opioid use disorder (OUD)
- ✓ Implement shared decision-making practices with patients evaluating OUD treatment options after TdP associated cardiac arrest
- ✓ Recognize the role for secondary prevention ICD in patients with a history of TdP associated cardiac arrest who wish to continue methadone for the treatment of OUD

CASE INFORMATION

HPI

- A 44-year-old female with a history of severe opioid use disorder (OUD) on methadone 165mg daily with recent fentanyl use for the last 3 weeks, anxiety on daily unprescribed benzodiazepine, alcohol use disorder in remission, and prolonged QT resulting in cardiac arrest due to Torsades de Pointes (TdP), presented to our academic medical center with a seizure after abruptly stopping her benzodiazepine.

PRIOR HOSPITALIZATION

- A year and a half prior, she suffered a cardiac arrest secondary to TdP due to prolonged QT of 640ms thought to be multifactorial from severe electrolyte abnormalities, alcohol withdrawal, and medication-induced from methadone and ondansetron.
- Electrophysiology was consulted at that time and did not recommend an implantable cardioverter defibrillator (ICD) given her arrest was due to reversible causes.
- Addiction medicine was consulted and initiated her on buprenorphine. However, buprenorphine was ineffective, and she was ultimately restarted on methadone in the outpatient setting with close electrocardiogram (EKG) monitoring.

HOSPITAL COURSE

- In her current admission, her QT was 607ms and as a result her methadone was held.
- Shortly after her admission, she went into cardiac arrest secondary to TdP due to prolonged QTc with return of spontaneous circulation obtained after one round of CPR.
- She had a strong desire to continue methadone as it had significantly helped in her treatment of OUD, while acknowledging multiple prior failed attempts on buprenorphine as well as suffering two episodes of cardiac arrest.
- Given her continued risk of future TdP associated cardiac arrest, electrophysiology offered and proceeded with secondary prevention dual chamber ICD implantation.
- Addiction medicine then assisted with up titration of her methadone. She was discharged on methadone 120mg total daily dosing with close follow up at her opioid treatment program (OTP).
- She remains in sustained remission on methadone therapy with stable device interrogation without any events at her one-year ICD follow up.

FIGURE

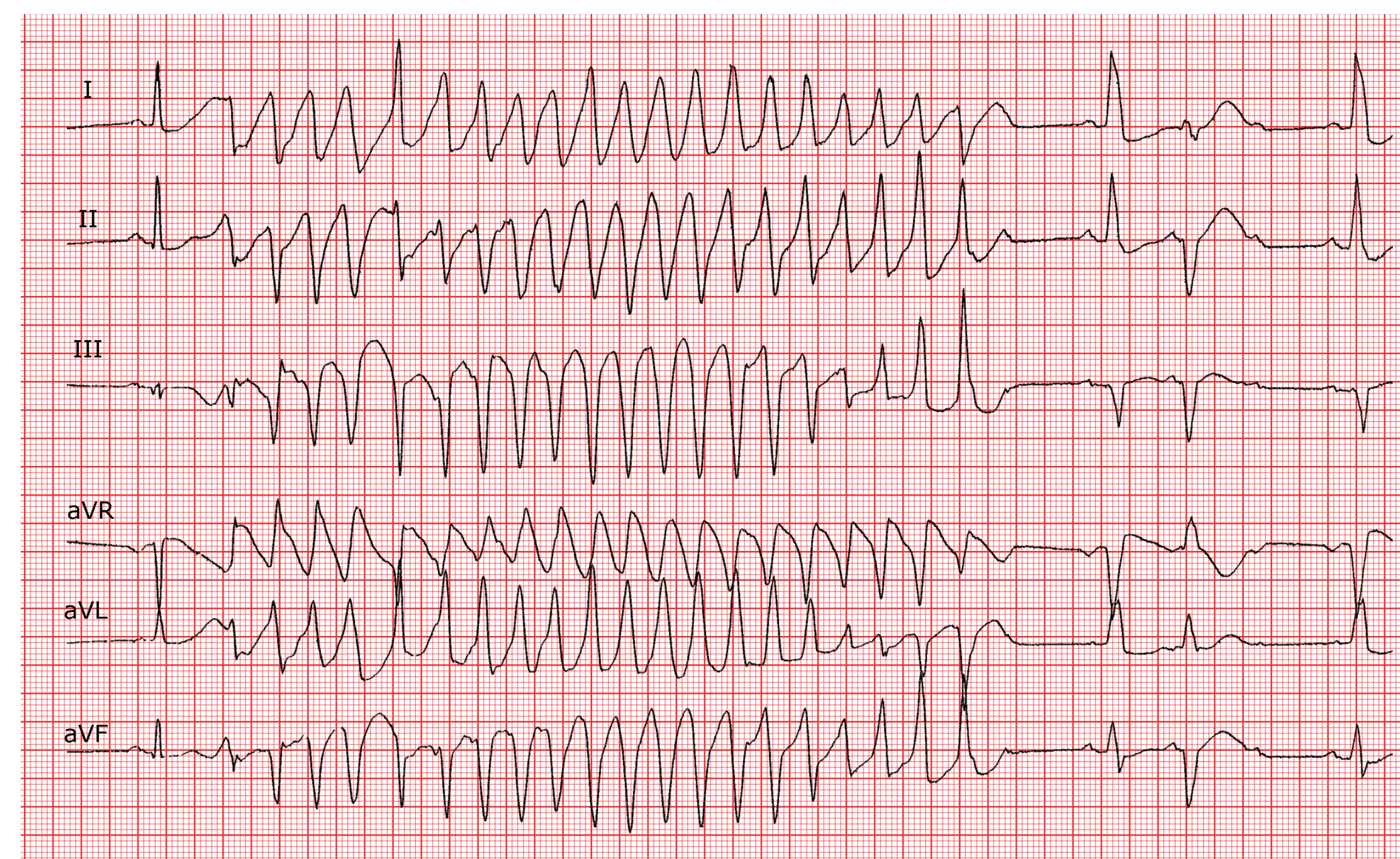


Figure 1. Example EKG showing Torsade de pointes with long QT syndrome.

REFERENCES

- Larochelle, M. R., Bernson, D., Land, T., Stopka, T. J., Wang, N., Xuan, Z., Bagley, S. M., Liebschutz, J. M., & Walley, A. Y. (2018). Medication for opioid use disorder after nonfatal opioid overdose and association with mortality. *Annals of Internal Medicine*, 169(3), 137. <https://doi.org/10.7326/m17-3107>
- Patel AM, Singh JP, Ruskin JN. Role of implantable cardioverter-defibrillators in patients with methadone-induced long QT syndrome. *Am J Cardiol*. 2008 Jan 15;101(2):209-11. doi: 10.1016/j.amjcard.2007.07.068. PMID: 18178408.
- Pearce, L. A., Min, J. E., Piske, M., Zhou, H., Homayra, F., Slaunwhite, A., Irvine, M., McGowan, G., & Nosyk, B. (2020). Opioid agonist treatment and risk of mortality during opioid overdose public health emergency: Population Based Retrospective Cohort Study. *BMJ*, m772. <https://doi.org/10.1136/bmj.m772>
- Santo, T., Clark, B., Hickman, M., Grebely, J., Campbell, G., Sordo, L., Chen, A., Tran, L. T., Bharat, C., Padmanathan, P., Cousins, G., Dupouy, J., Kelty, E., Muga, R., Nosyk, B., Min, J., Pavarin, R., Farrell, M., & Degenhardt, L. (2021). Association of opioid agonist treatment with all-cause mortality and specific causes of death among people with opioid dependence. *JAMA Psychiatry*, 78(9), 979. <https://doi.org/10.1001/jamapsychiatry.2021.0976>
- Treece, J.M., Al Madani, M., El Khoury, G., Khraisha, O., Martin, J.E., Baumrucker, S.J., Neglia, C.A., & Paul, T.K. (2018). Comprehensive Review on Methadone-Induced QT Prolongation and Torsades. *Journal of Pharmacology and Pharmacotherapeutics*. Vol.9(2). 66-75. <https://doi.org/10.4103/jpp.JPP-163-17> ISSN: 0976-500X
- Wakeman, S. E., Larochelle, M. R., Ameli, O., Chaisson, C. E., McPheeters, J. T., Crown, W. H., Azocar, F., & Sanghavi, D. M. (2020). Comparative effectiveness of different treatment pathways for opioid use disorder. *JAMA Network Open*, 3(2). <https://doi.org/10.1001/jamanetworkopen.2019.20622>

DISCUSSION

- Methadone is a life-saving treatment for patients with OUD with current evidence that repeatedly shows that it reduces mortality and overdoses by up to 50%, making it one of the most effective medications we have available in medicine.
- Methadone has the risk of causing QT interval prolongation, especially at higher doses and in patients with other risk factors for QT prolongation, potentially leading to TdP.
- The true incidence of QT prolongation and TdP with methadone is difficult to determine due to different definitions of reference values and other numerous predisposing risk factors that can contribute to QT prolongation.
- Even though the incidence of QT prolongation in the setting of methadone use is not rare, the development of TdP is rare.
- QT prolongation can limit and exclude the use of methadone for the treatment of OUD.
- Methadone is viewed as a reversible cause of QT prolongation resulting in the lack of consideration of ICD prevention therapy in this patient population.
- Stopping methadone places patients at high risk for return to use, overdose, and death.
- Prior case series suggest that ICDs may be lifesaving in patients who continue methadone therapy after an episode of TdP.
- In the era of fentanyl, there is a need for individualized and patient-centered approaches in the treatment of OUD.

CONCLUSION

- This case highlights thoughtful multidisciplinary discussion and shared decision making surrounding the consideration and ultimate offering and placement of secondary prevention ICD to a patient with a history of TdP associated cardiac arrest who had previously failed buprenorphine therapy and had a strong preference to continue methadone therapy.