



Background

- Tooth-specific developmental delay (TSDD) describes a phenomenon observed in the permanent dentition in which a tooth is significantly delayed in eruption beyond normal variance, in the absence of mechanical obstruction.
- Previous literature has described this phenomenon as “nine-year molars” when the first molar was affected.
- In prior literature, teeth erupt into the oral cavity without additional clinical intervention, distinguishing this condition from primary failure of eruption (PFE).

Case Presentation

- **Patient:** 16-year-old male
- **Chief Complaint:** Crowding of teeth
- **Medical History:**
 - Premature birth
 - Tonsillar hypertrophy
 - Otitis media
 - Urinary reflux
 - Azithromycin allergy
- **Surgical History:** Tympanostomy
- **Clinical Findings:**
 - Delayed eruption of #18
 - High caries risk
- **Radiographic Findings:**
 - Delayed eruption of #18 with incomplete root development
 - Supra-eruption of #15
 - Elongated styloid process

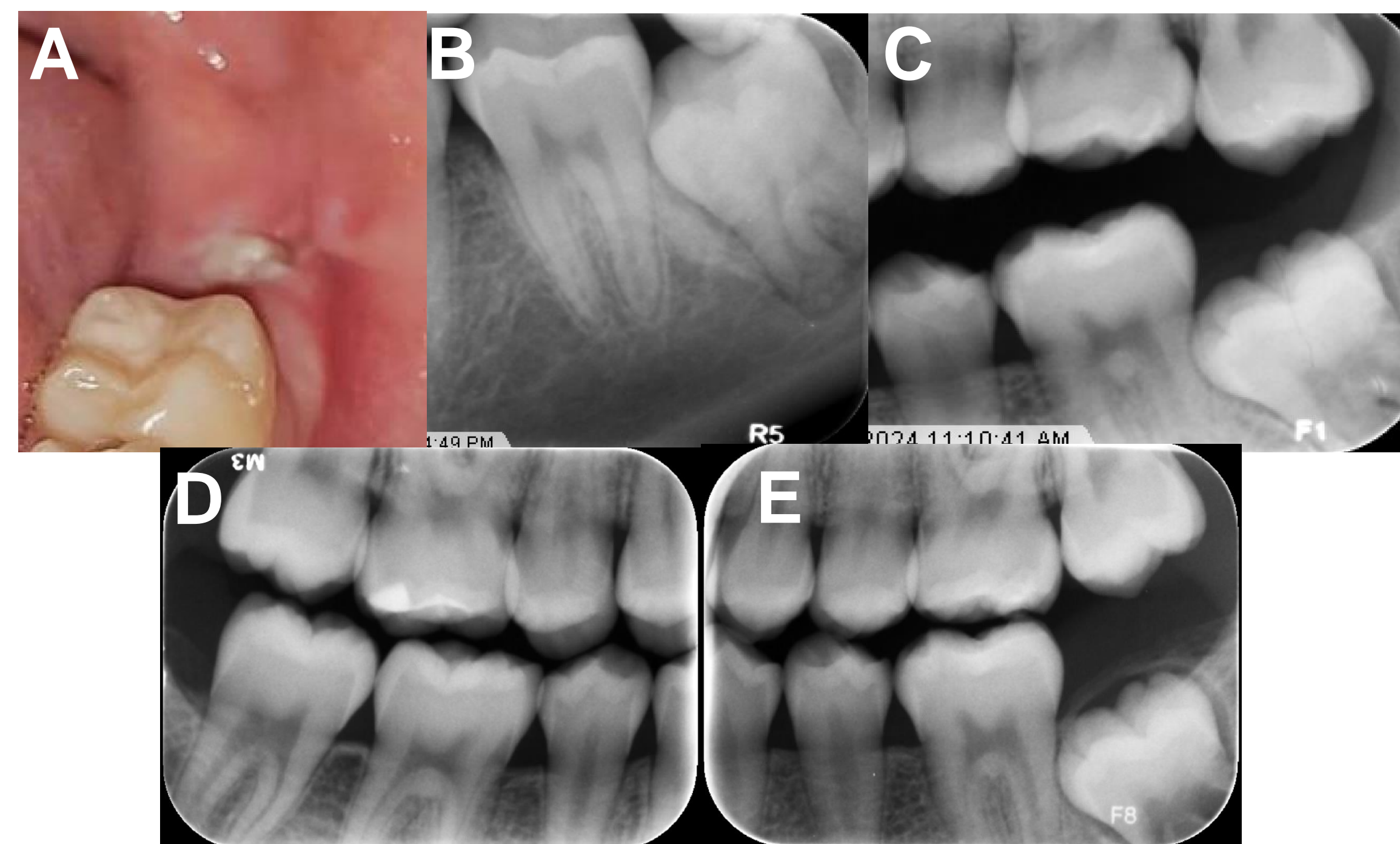


Figure 1: Intraoral photograph of the affected region (A), Periapical radiographs of the affected tooth #18 (B), Supra-eruption of opposing tooth #15 (C), Bitewings from two years prior with delayed eruption of #18 (D,E)

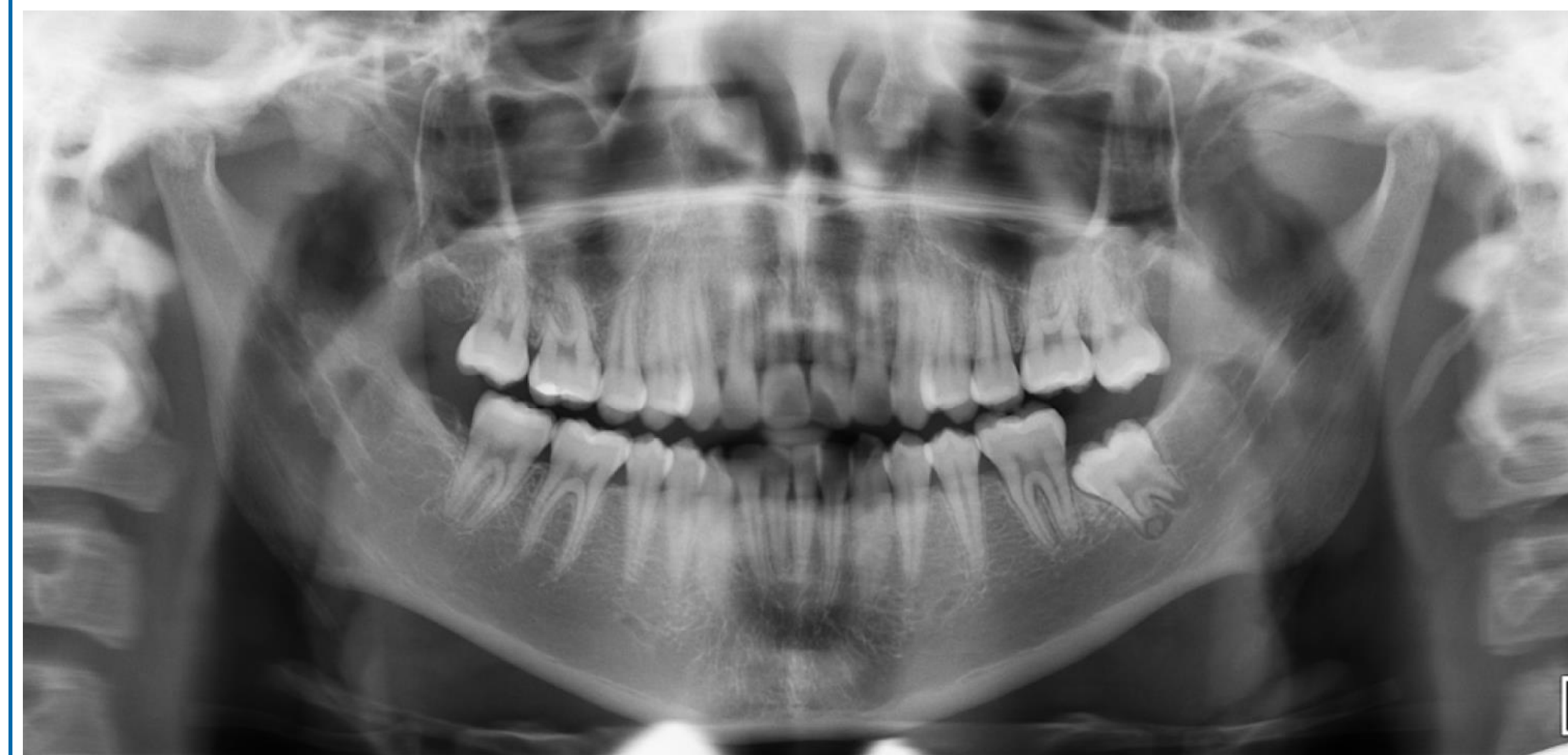

Figure 2: Panoramic radiograph demonstrating the affected tooth, in relation to the entire dentition

Discussion

- Tooth eruption is known to be a multifactorial process, integrating both a genetic and physiologic component.
- This case presentation is most analogous to primary failure of eruption (PFE), displaying similarities such as multiple adjacent teeth being affected. However, PFE is associated with specific genetic mutations.
- This present patient does not have any known prior history or diagnosis of inherited genetic conditions, or a known contributory maternal social history.
- The occurrence of TSDD in this patient represents a later presentation than previously described in literature.

Conclusions

- Tooth-specific developmental delay represents more accurate nomenclature for this condition, as this case shows that delayed eruption can occur outside of previously described age group.
- TSDD is a distinct condition from PFE
- Further study of TSDD is indicated to determine causative factors and predict outcome

References

- Klein U et al. Maxillary Nine-year Molars: Prevalence and Associated Dental and Medical Conditions. 38(3).
- Rasmussen P. “9-year-molars” aberrantly developing and erupting; report of cases.
- Aharon ED et al. Impacted permanent first and second molars and failure of eruption: A comprehensive review for the orthodontic practitioner. *Seminars in Orthodontics*. 2024;30(5):727-741.
- Yu T, et al. Molecular and cellular mechanisms of tooth development, homeostasis and repair. *Development*. 2020;147(2):dev184754.