

Recurrent Sialadenitis and Sialendoscopic Analysis: Single Institution Review

Emily Kwon, BA¹; Annie Xu, BS¹; Rushikesh Pande, BS¹; Sebastian De Armas, MD¹; Evelyne Kalyoussef, MD¹

¹ Department of Otolaryngology, Rutgers New Jersey Medical School, Newark, NJ

Introduction

Sialadenitis is defined as inflammation or infection of the salivary glands due to infectious, obstructive, or autoimmune etiologies.¹ In patients with recurrent sialadenitis (RS), interventional sialendoscopy is an effective diagnostic and therapeutic tool.² Sialendoscopy allows for direct visualization of the salivary ducts along with concurrent therapeutic interventions.³ Our study aims to investigate the efficacy of sialendoscopy in RS and identify endoscopic findings which may predict patients at risk for recurrent disease requiring repeat operative interventions.

Methods

- Retrospective review of 101 patients with RS at a tertiary medical center between 2015-2023 who underwent sialendoscopy.
- RS was defined as ≥ 3 documented episodes of painful gland swelling.
- Demographic characteristics, smoking history, autoimmune disease history, and history of radioactive iodine therapy (RAI) were compared between patients with persistent sialadenitis and those without recurrence following the initial sialendoscopy. Between these groups, sialendoscopy findings (presence of sialoliths, debris/sludge, fibrosis/blanching, and stenosis/strictures) were reviewed.
- Sialendoscopy findings were compared between patients with and without a history of RAI.
- Analysis was done using Chi-square test, Fisher's exact test, two-tailed t-test, using SPSS 29.0. Significance set at $p < .05$.

Results

Variable	Resolved Sialadenitis (n=81)	Persistent Sialadenitis (n=20)
Gender		
Male	39 (38.6%)	6 (5.9%)
Female	42 (41.6%)	14 (13.9%)
History of RAI		
Yes	5 (5%)	3 (3%)
No	76 (75.2%)	17 (16.8%)
History of Autoimmune Disease or Documented Suspicion		
Yes	10 (9.9%)	3 (3%)
No	71 (70.3%)	17 (16.8%)
History of Smoking		
Yes	26 (25.7%)	4 (4%)
No	55 (54.5%)	16 (15.8%)

Table 1. Patient demographics and clinical characteristics of patients who underwent sialendoscopy.

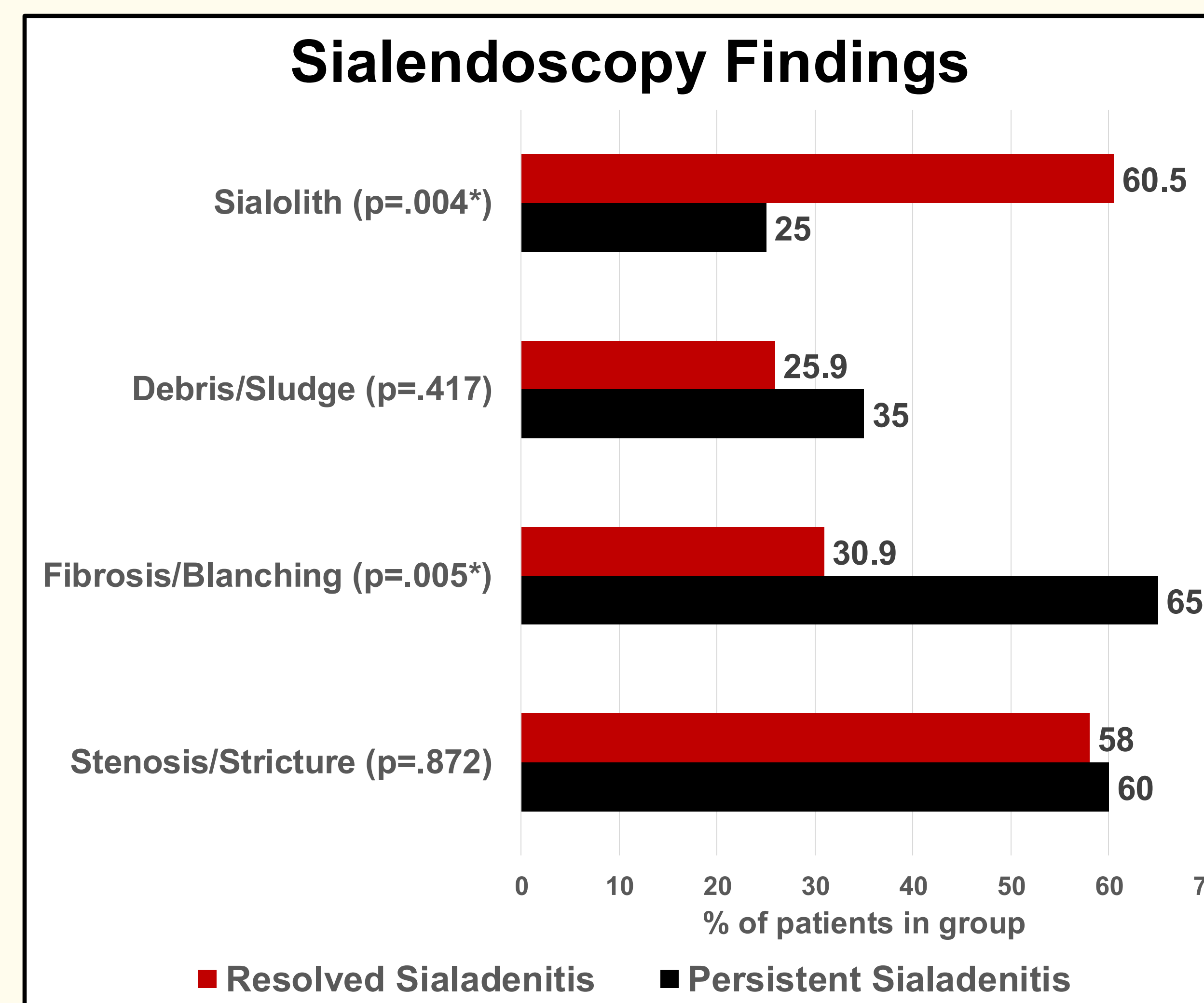


Figure 2. Comparison of sialendoscopic findings between recurrent and nonrecurrent sialadenitis.

Sialendoscopy Findings	No History of Radioactive Iodine Therapy (n=93)	History of Radioactive Iodine Therapy (n=8)	P value
Fibrosis/Blanching of Ductal Mucosa			.023
Yes	61 (60.4%)	6 (5.9%)	
No	32 (31.6%)	2 (2%)	
Sialolithiasis			.015
Yes	53 (52.4%)	1 (1%)	
No	40 (39.6%)	7 (6.9%)	
Stenosis/Stricture			.321
Yes	53 (52.5%)	6 (5.9%)	
No	40 (39.6%)	2 (2%)	
Debris/Sludge			.52
Yes	25 (24.8%)	3 (3%)	
No	68 (67.2%)	5 (5%)	

Table 2. Association of prior radioactive iodine therapy with sialendoscopic findings.

Results

We evaluated 101 cases involving patients who underwent sialendoscopy. These patients underwent 118 procedures in total, with 14 requiring more than 1 procedure and 3 requiring more than 2. Symptom resolution was achieved in 91.8% of submandibular cases (n=61) and 63.4% of parotid cases (n=41). No significant differences were found among demographic data, smoking history, autoimmune history, or operative findings like ductal stenosis and debris between the resolved and persistent group.

The **persistent group** was more likely to have **chronic inflammation** in the form of ductal fibrosis, mucosal pallor, or hypervascularity ($p=.005$), while the **resolved group** was more likely to have **sialolithiasis** ($p=.004$). Patients with a history of **RAI** were associated with **chronic inflammatory changes** in the form of ductal fibrosis, mucosal pallor, or hypervascularity ($p=.023$) and **less likely to present with sialolithiasis** ($p=.015$) compared to patients without a history of RAI.

Discussion

- Most patients achieved complete symptom resolution (80.2%) following sialendoscopic intervention, further supporting its effectiveness as a diagnostic and therapeutic tool in RS.
- Patients with sialoliths were less likely to experience recurrent symptoms, suggesting that sialadenitis in this setting is more consistent with isolated obstructive pathology rather than diffuse changes associated with chronic inflammatory disease, and that removal of the stone is often sufficient for long-term resolution.
- Intraoperative findings such as inflammatory changes may help predict the risk of recurrence, consistent with prior work suggesting that endoscopic parameters reflect the severity of underlying nonspecific chronic sialadenitis.⁴

Conclusion

- Patients with signs of **chronic inflammation** may be more likely to require further operative intervention, as they are **less likely** to have **symptom resolution** following sialendoscopy.
- The presence of **sialoliths** may be a **favorable** prognostic factor for maintaining a disease-free state post-sialendoscopy.
- Further research is needed to identify other patient characteristics that may guide treatments and reduce the need for recurrent interventions.

References

1. Moore, J., Simpson, M. T., Cohen, N., Beyea, J. A., & Phillips, T. (2023). Approach to sialadenitis. *Canadian Family Physician*, 69(8), 531-536.
2. Gallo, A., Martellucci, S., Fusconi, M., Pagliuca, G., Greco, A., De Virgilio, A., & De Vincentiis, M. (2017). Sialendoscopic management of autoimmune sialadenitis: a review of literature. *Acta Otorhinolaryngologica Italica*, 37(2), 148.
3. Atienza, G., & López-Cedrún, J. L. (2015). Management of obstructive salivary disorders by sialendoscopy: a systematic review. *British Journal of Oral and Maxillofacial Surgery*, 53(6), 507-519.
4. Bertram J, Nieri C, Reed L, Gillespie MB. Sialendoscopy Findings Associated with Positive Minor Salivary Gland Biopsy. *Laryngoscope*. 2023;133(10):2413-2417. doi:10.1002/lary.31085.