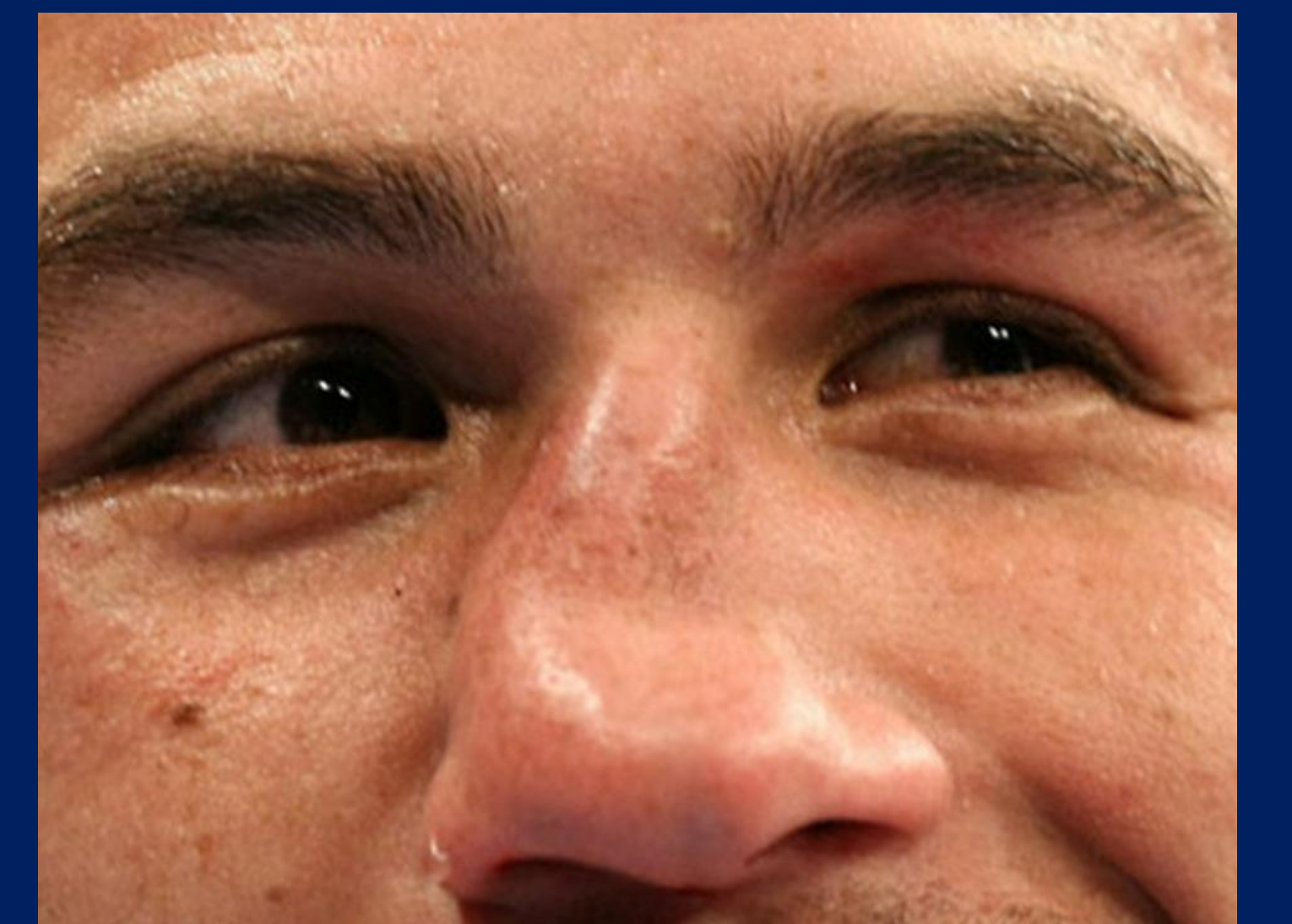

# The importance of tip in correction of the Deviated Nose

Mohsen Naraghi, MD, FARS<sup>1,2</sup>, Hamed Sarikhani, MD<sup>3</sup>



## Astract

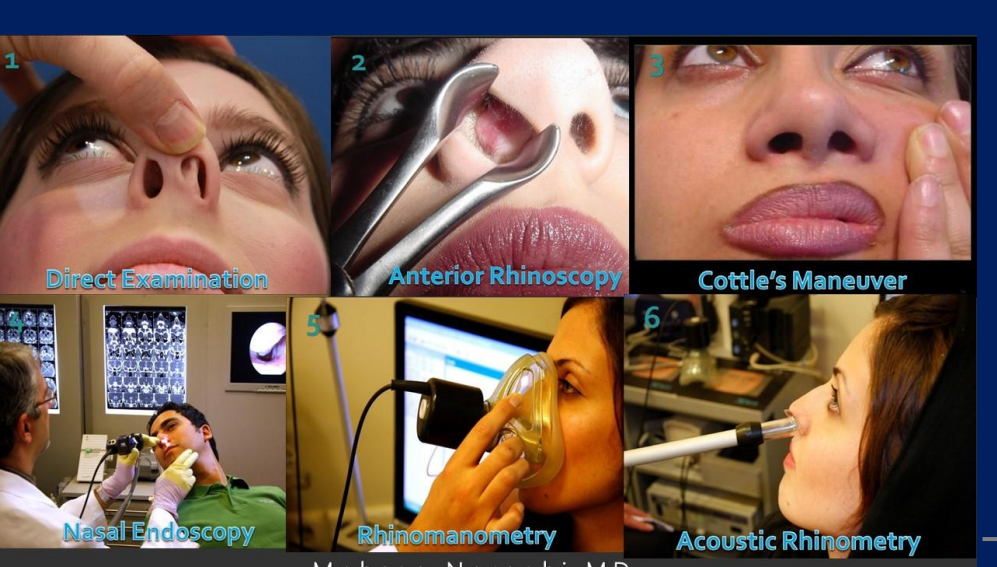
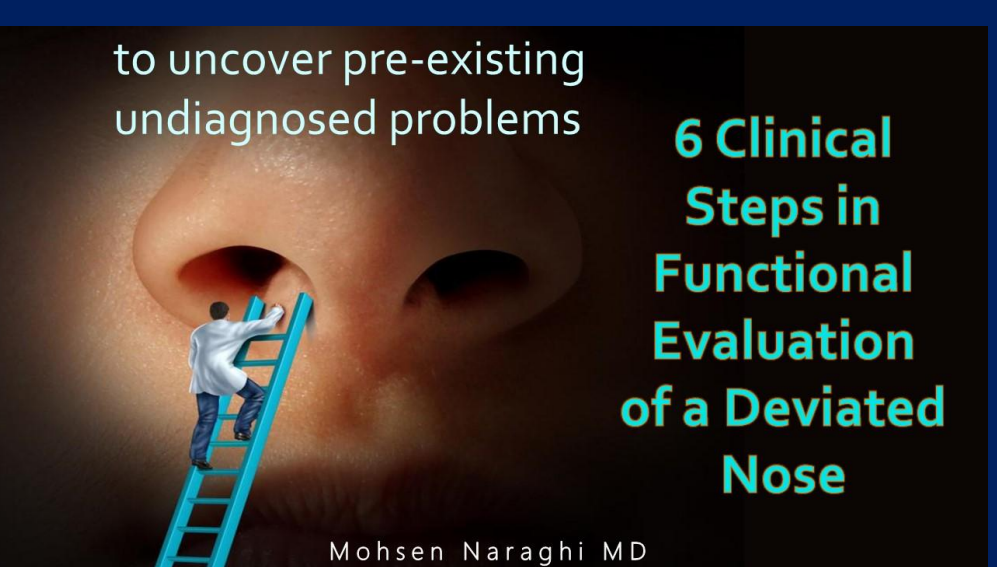
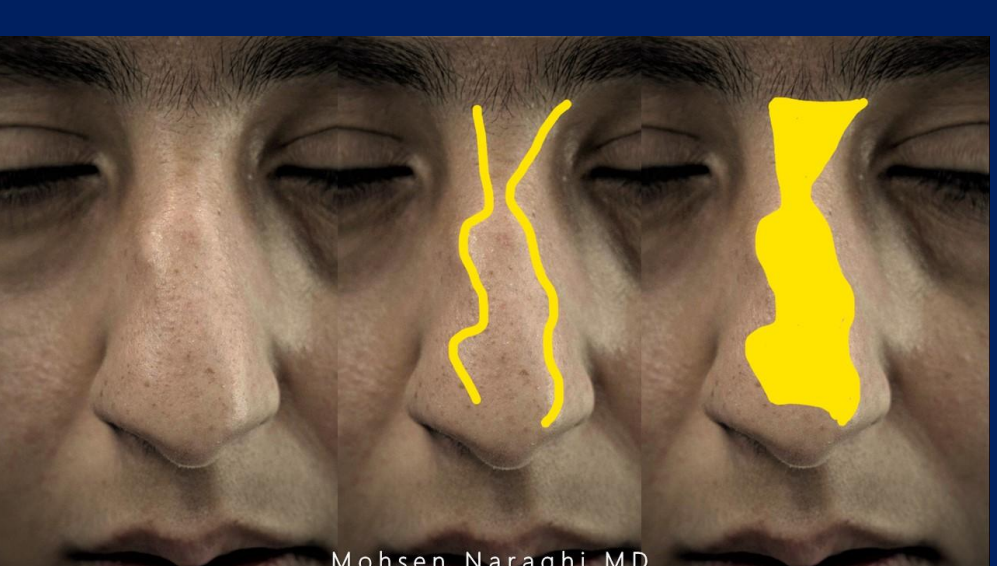
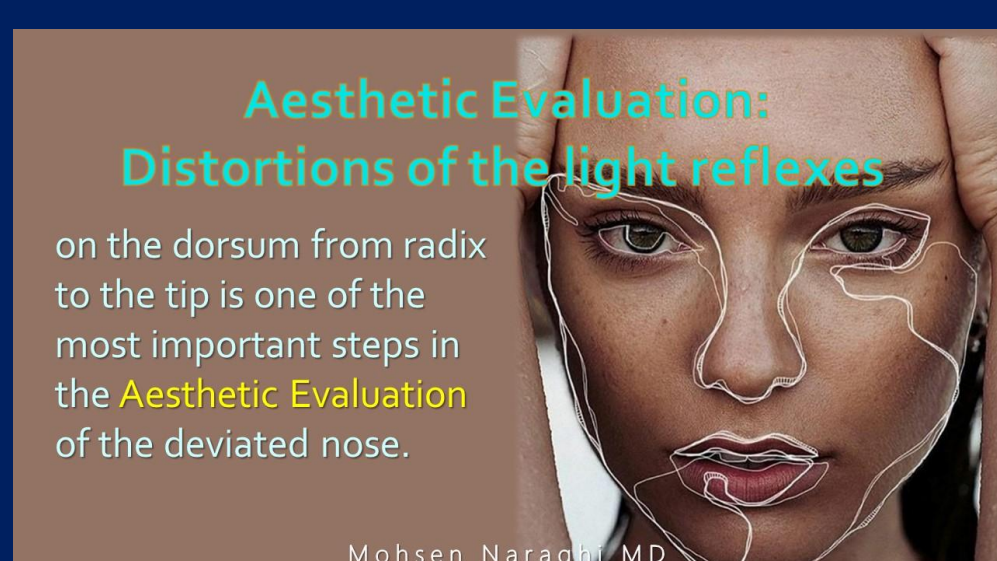
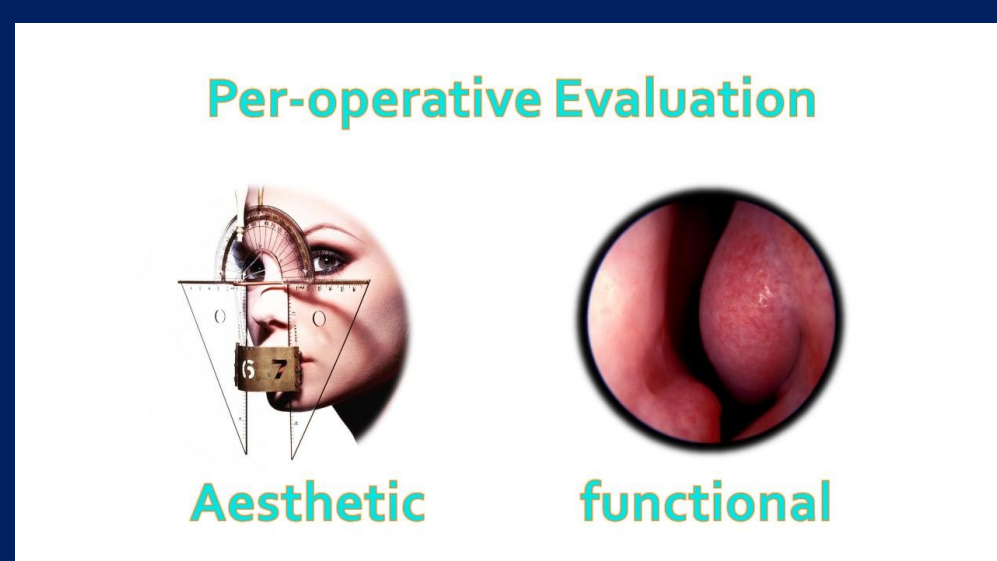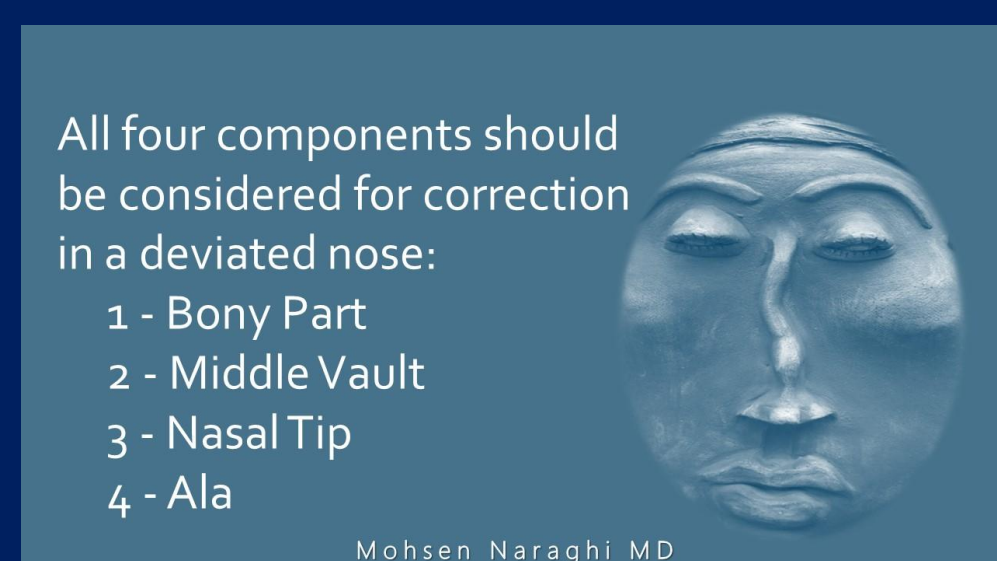
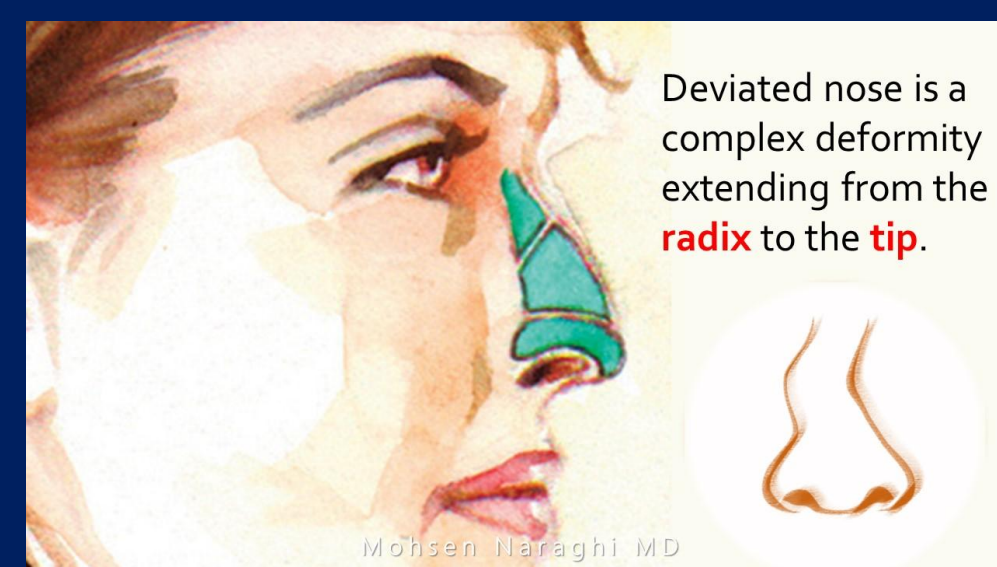
**Background:** Establishing stable and long-term results in the correction of the deviated nose has been a nightmare even for experienced surgeons. Most patients have problems both in form and function. Analyzing the underlying anatomy in each case is important to establish the plan of treatment that differs in every case.

**Methods:** Six hundred seventy selected deviated nose patients underwent different surgical procedures for correction of the deviated nose. More than three fourth of patients had a combination of more than four procedures to correct various aspects of deviation from radix to the tip. All types of deviated noses were operated in one stage with the correction of the pyramid and septum. Proper cuts and resections of cartilage and insertion of resected materials as different types of grafts were the basis of most techniques for correction.

**Results:** Correction of form and function included restoration of the straight dorsum, reducing asymmetries and providing a functionally patent nasal valve. There was an improvement in breathing and appearance of the nose with varying degrees in our cases. Improvement was more noticeable in patients with multiple procedures to correct the entire framework from the radix to the tip.

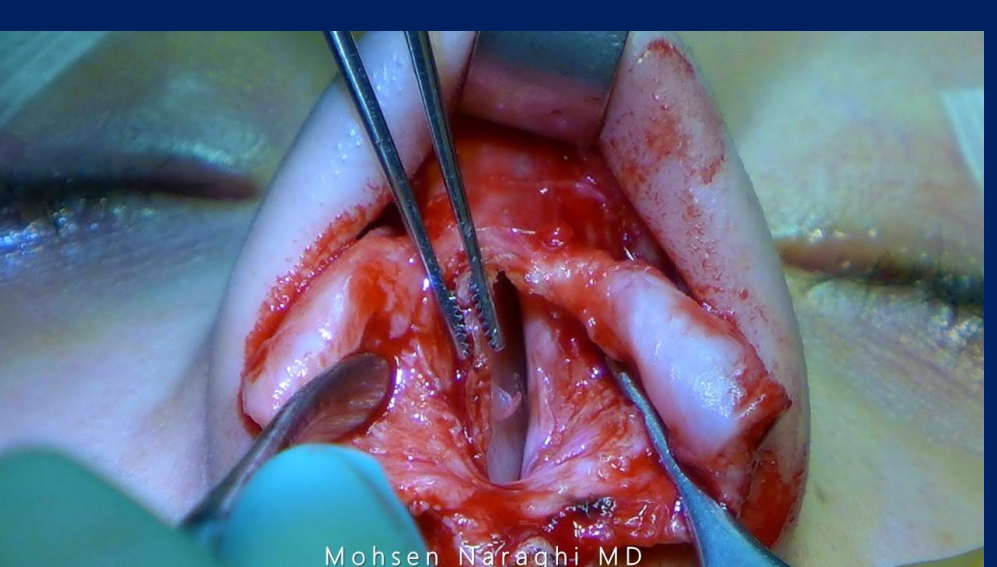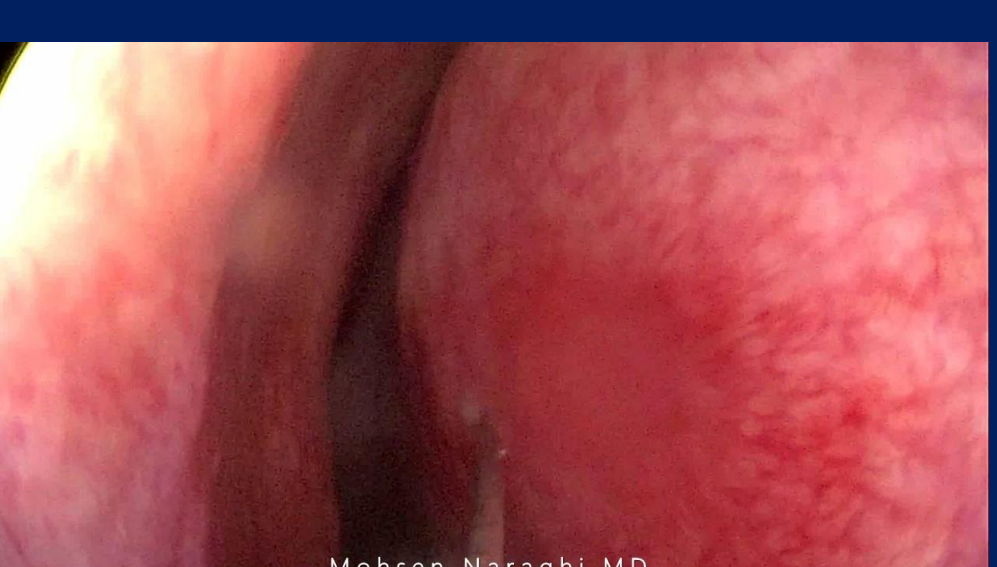
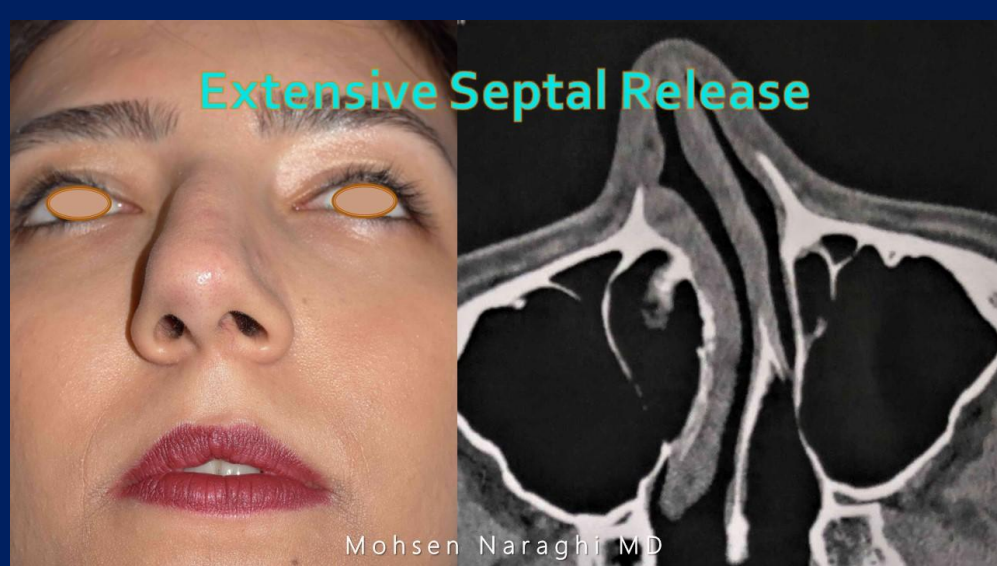
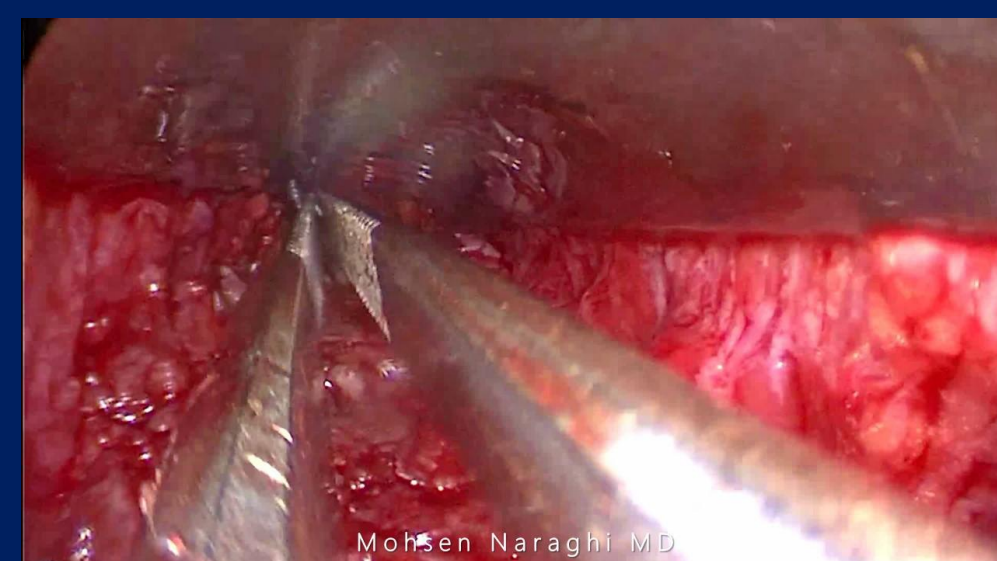
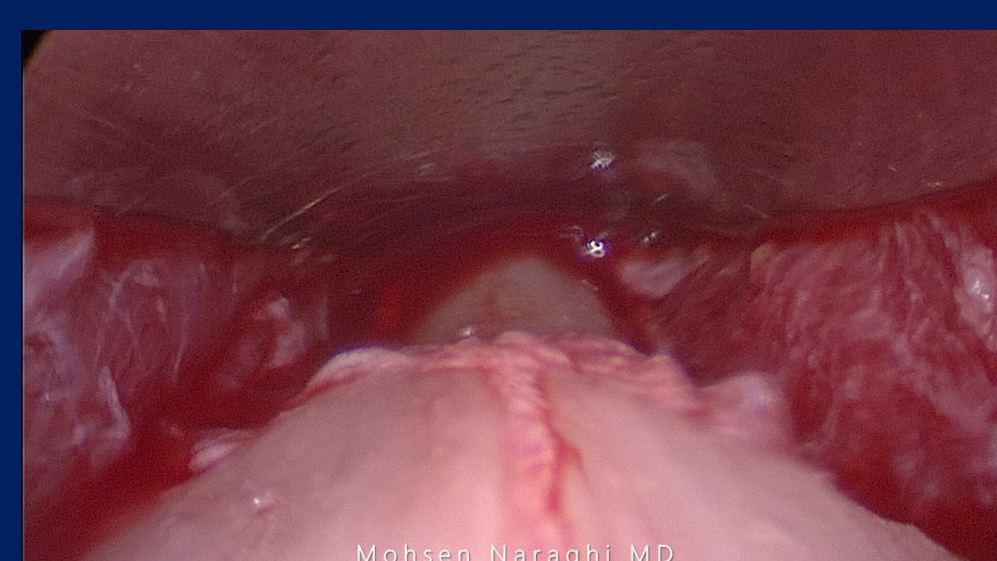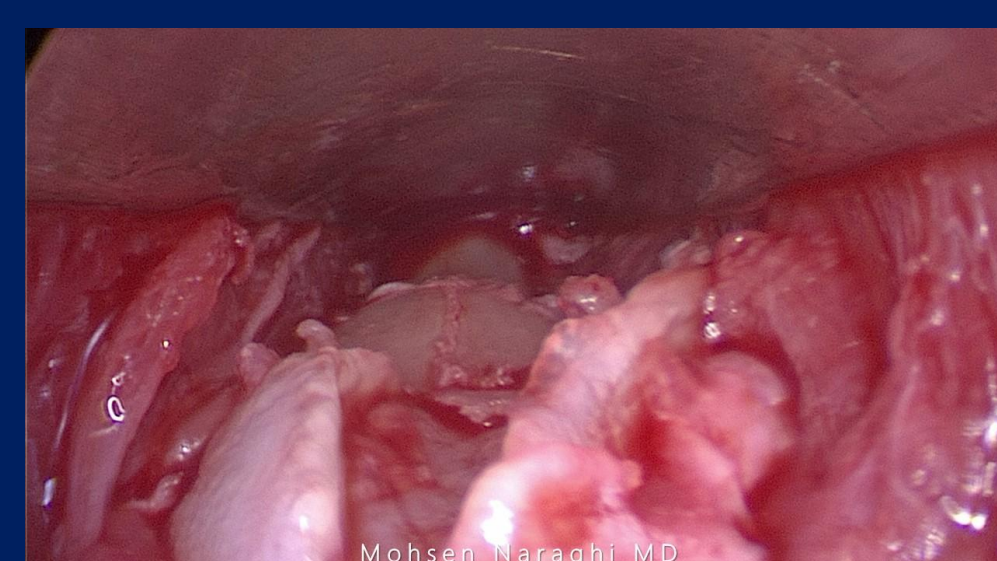
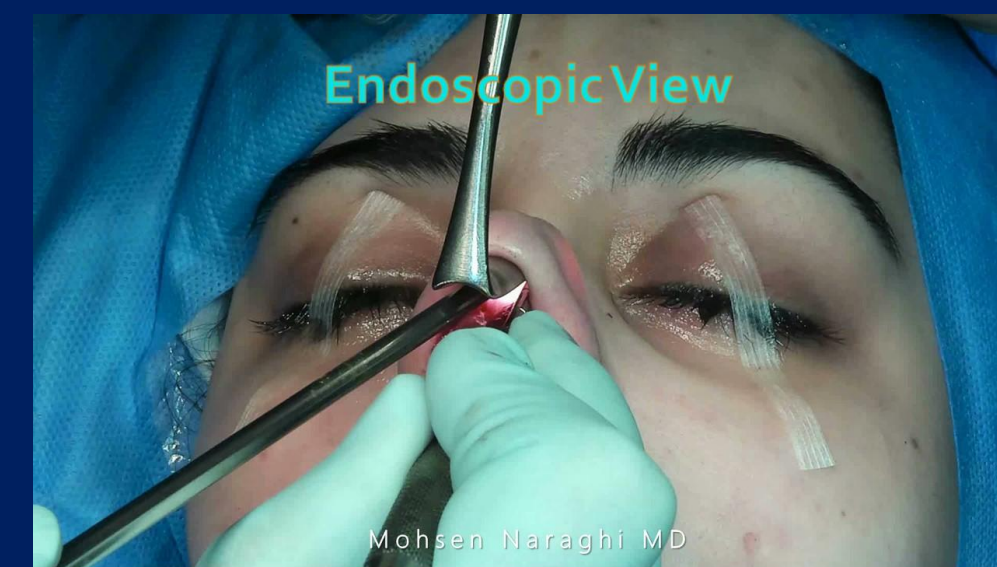**Conclusions:** The deviated nose is a complex deformity extending from the radix to the tip. Successful surgery is not possible without the correction of tip deformities and asymmetries as an important part of the procedure.  
**Key words:** rhinoplasty, deviated, nose, septum, septoplasty, crooked, nasal valve

## Evaluation

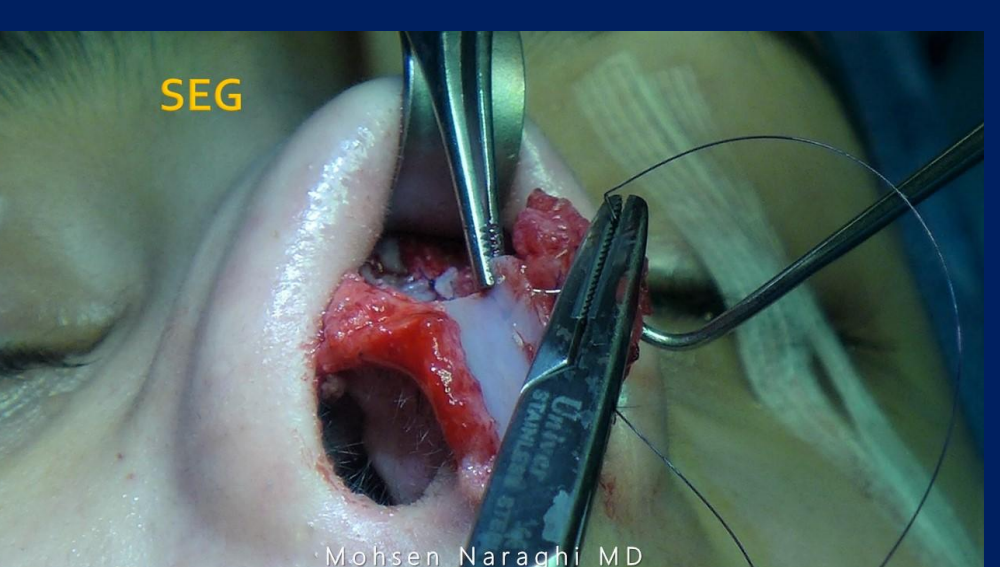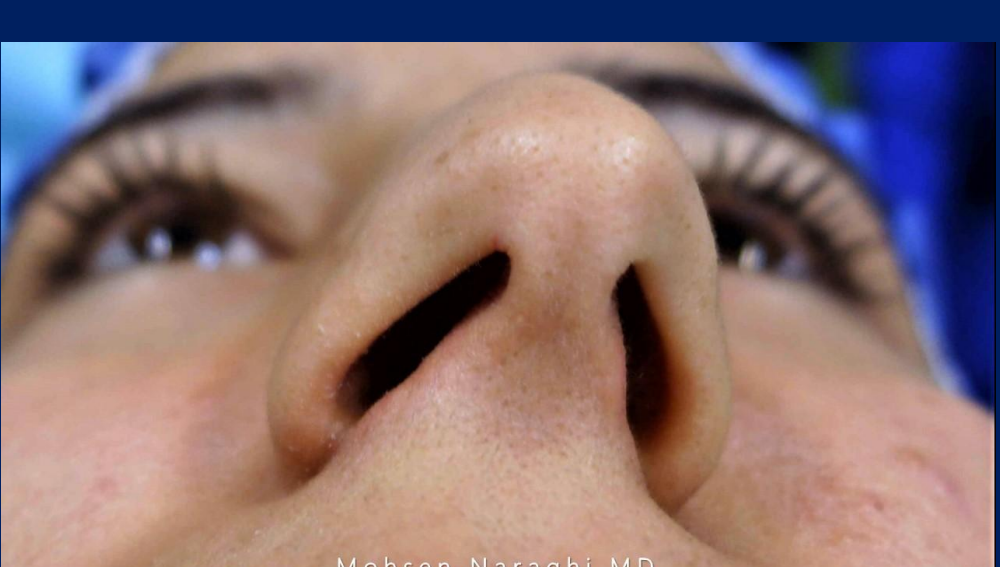
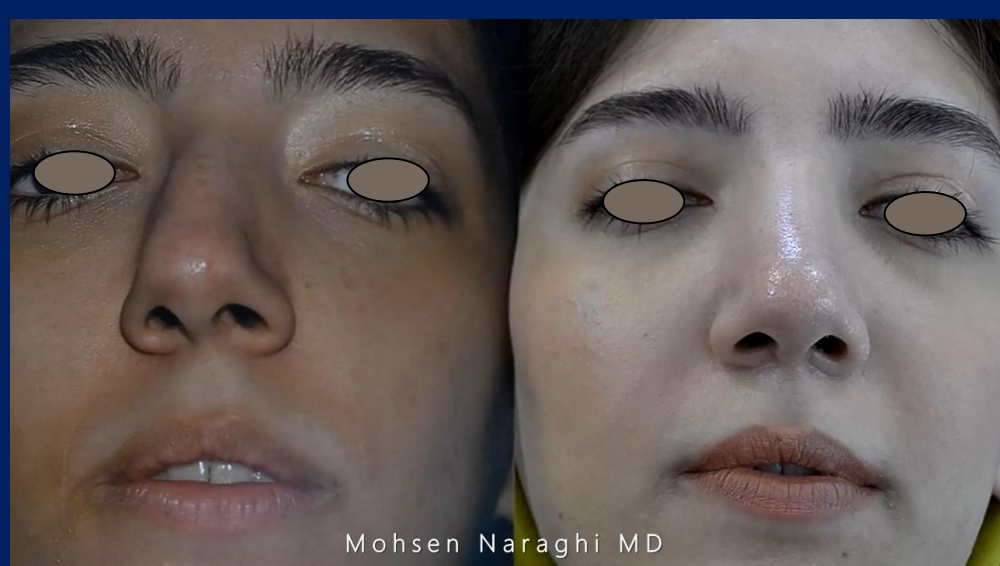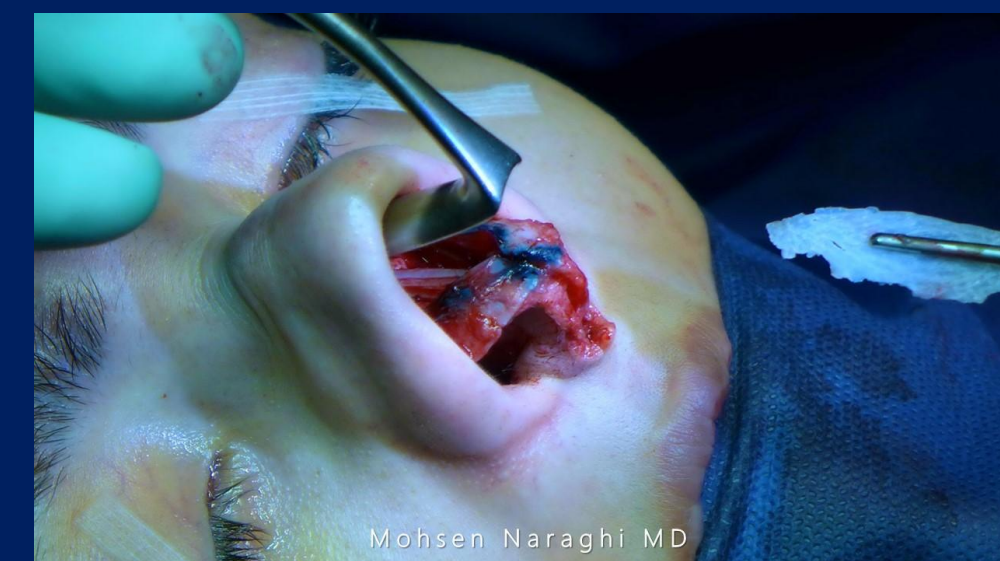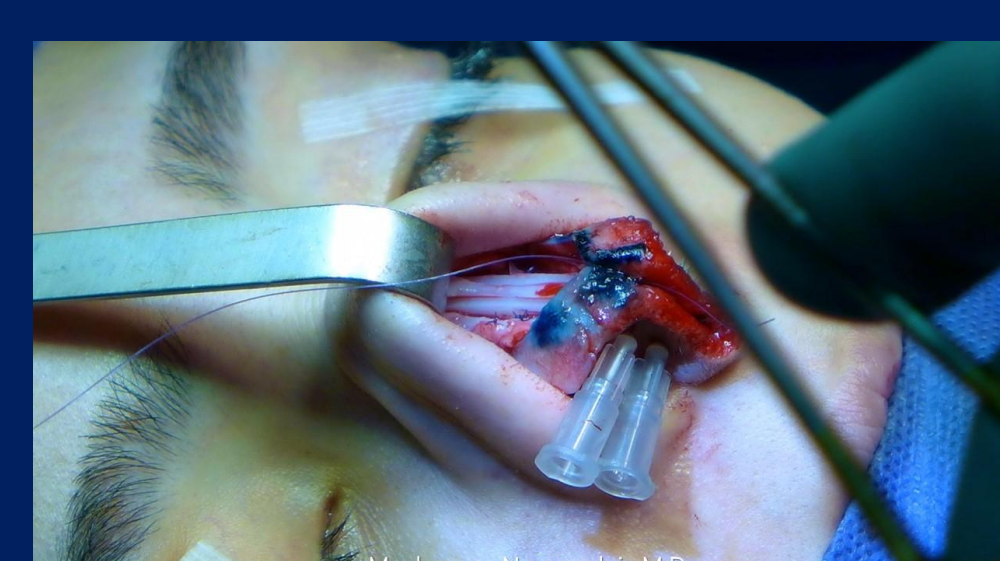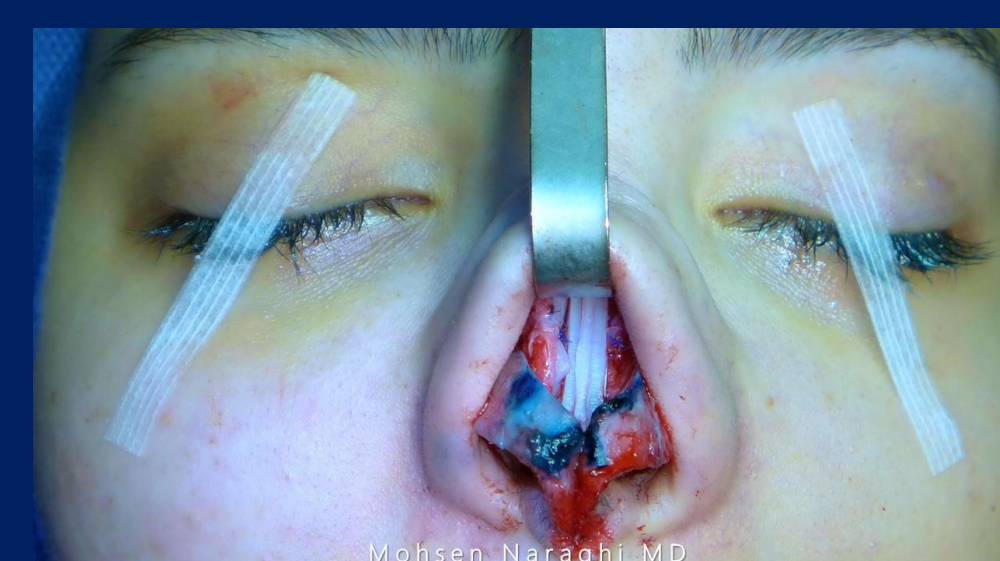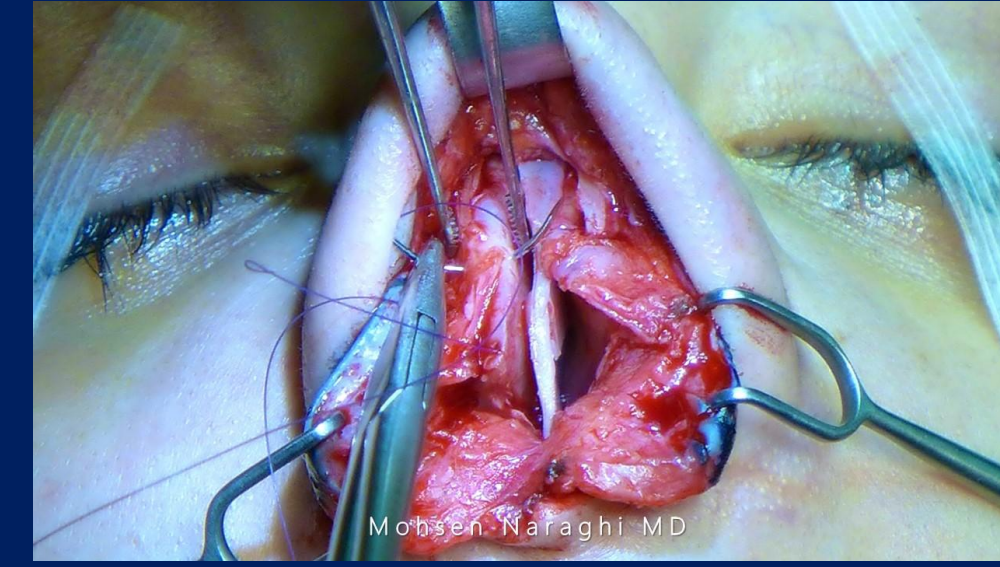


Mohsen Naraghi MD, FARS  
Email: [info@dr-naraghi.com](mailto:info@dr-naraghi.com)  
[dr\\_mohsen\\_naraghi](mailto:dr_mohsen_naraghi)

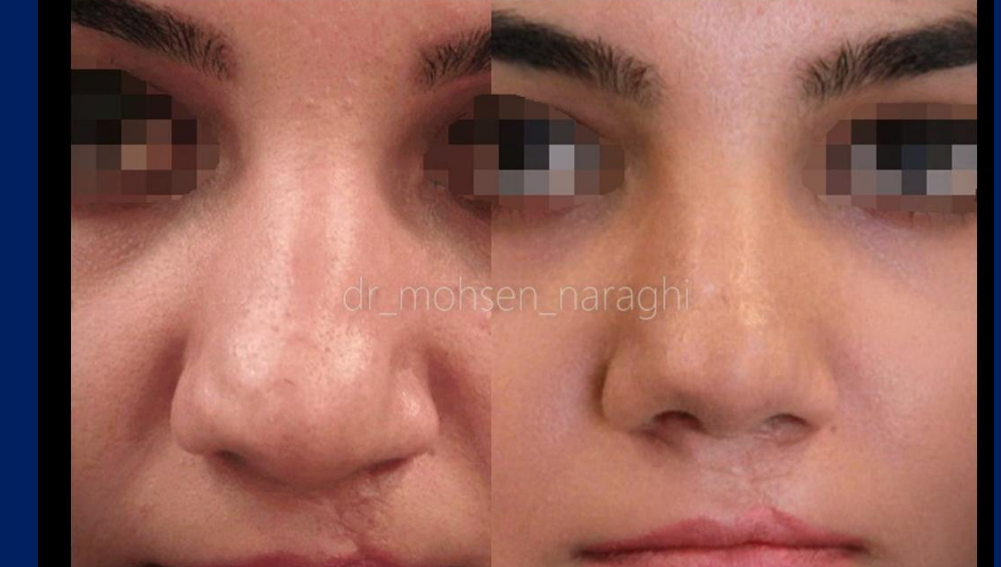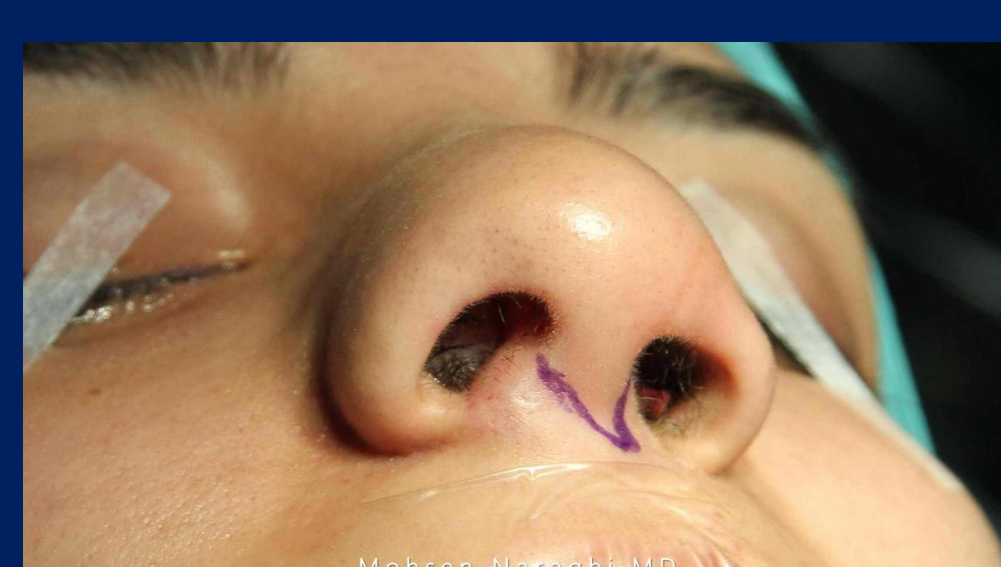
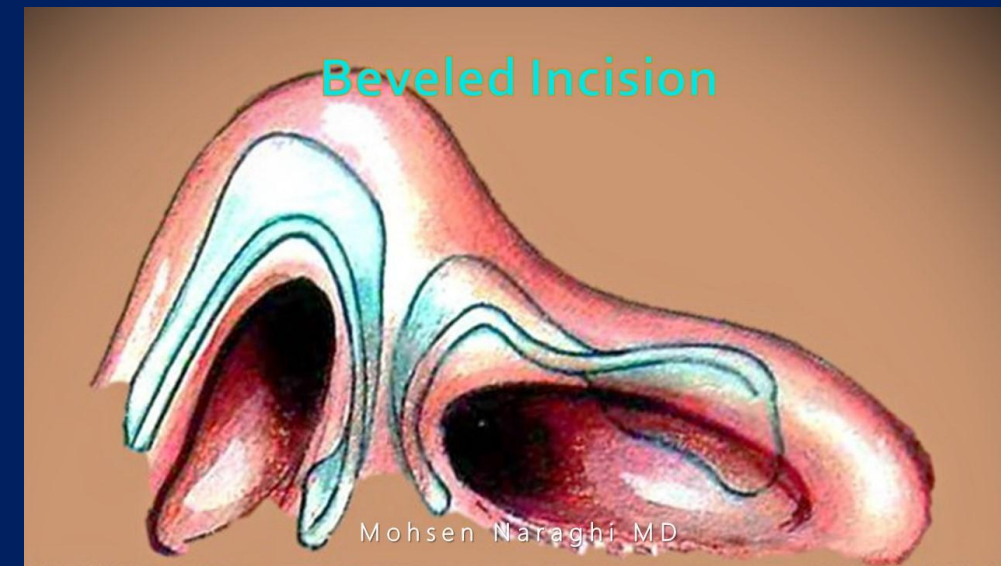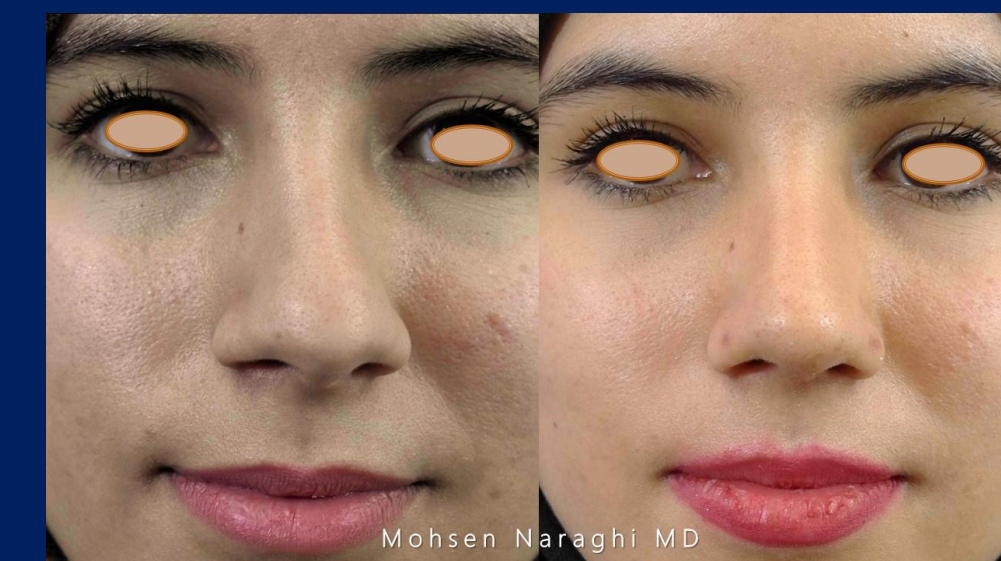
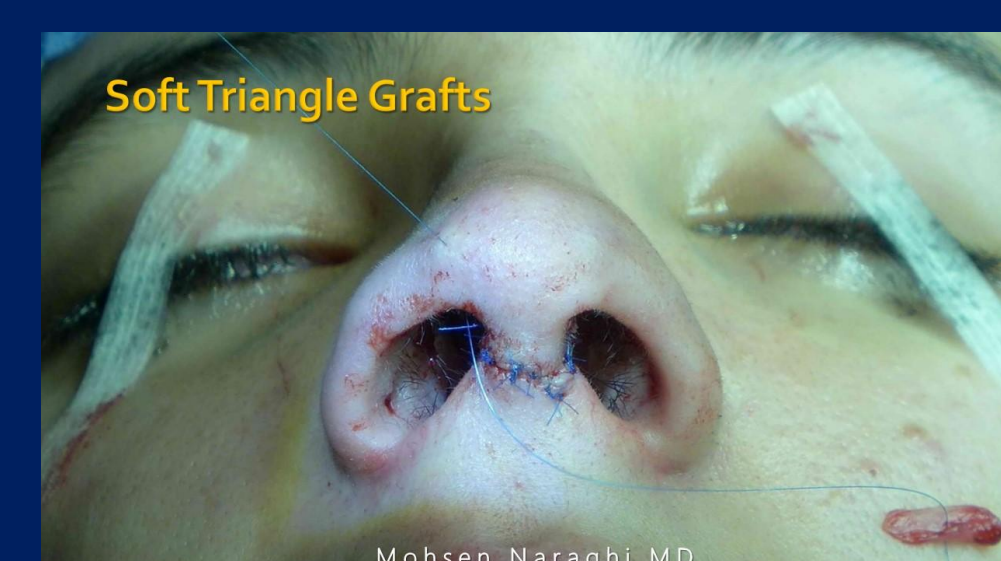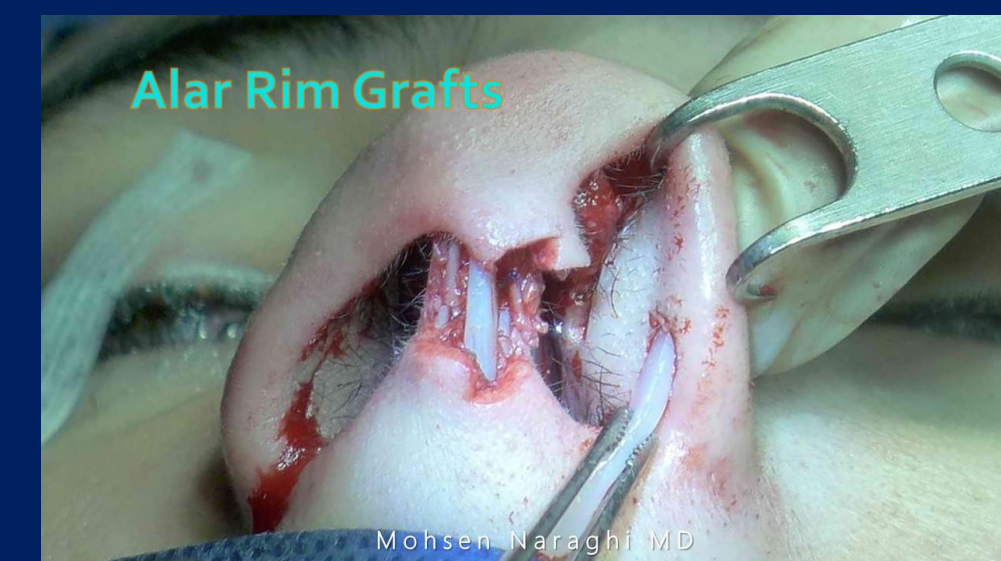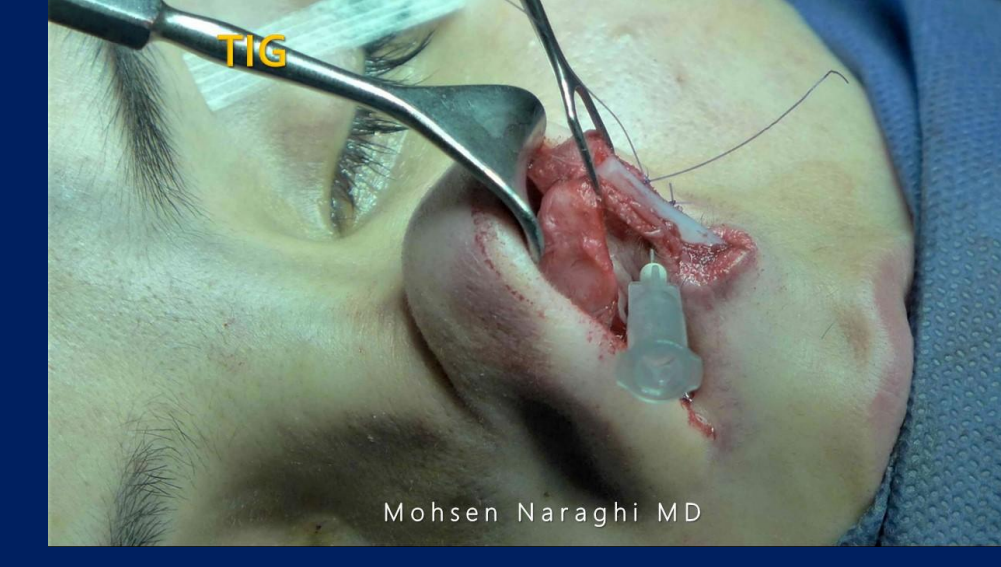## Basic Plans



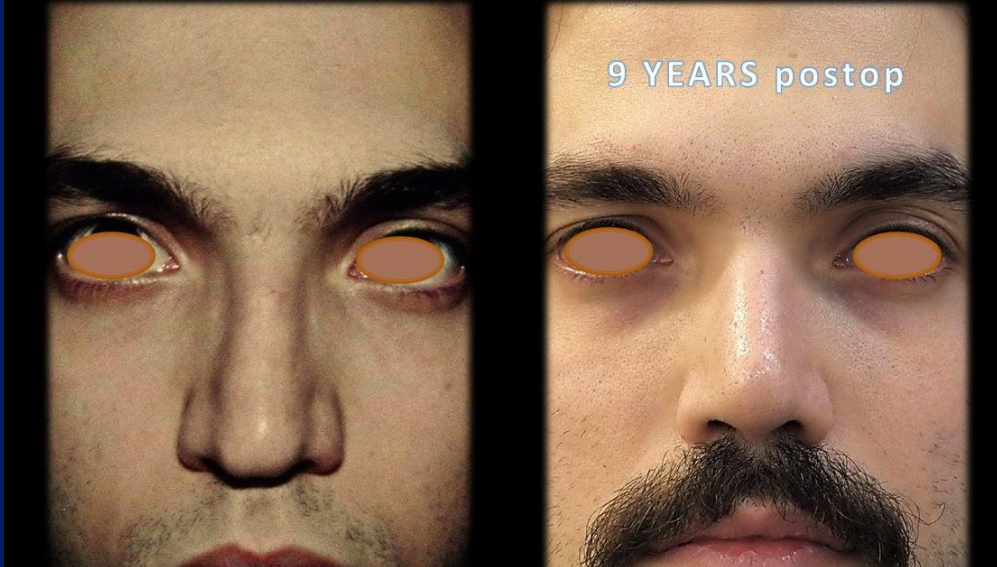

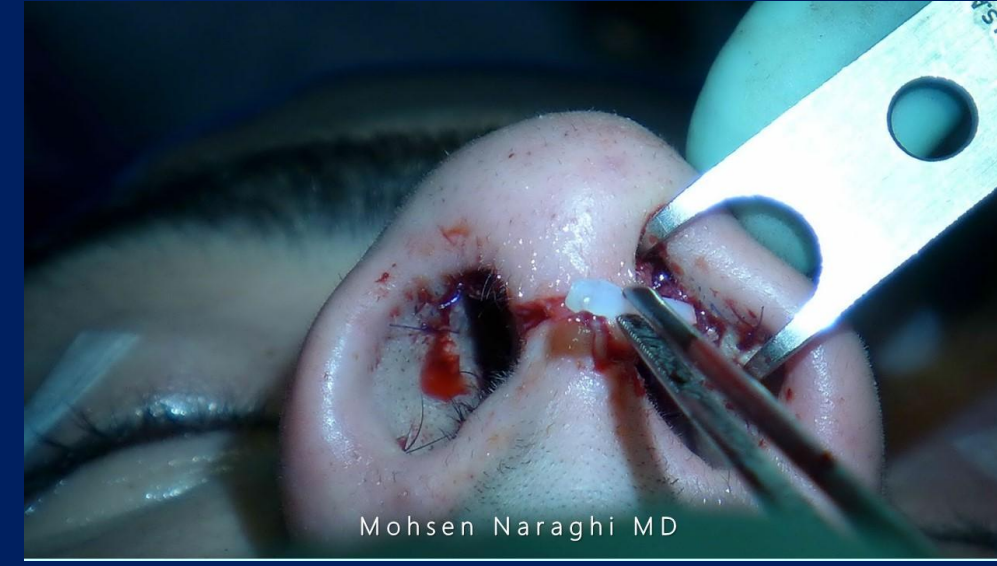
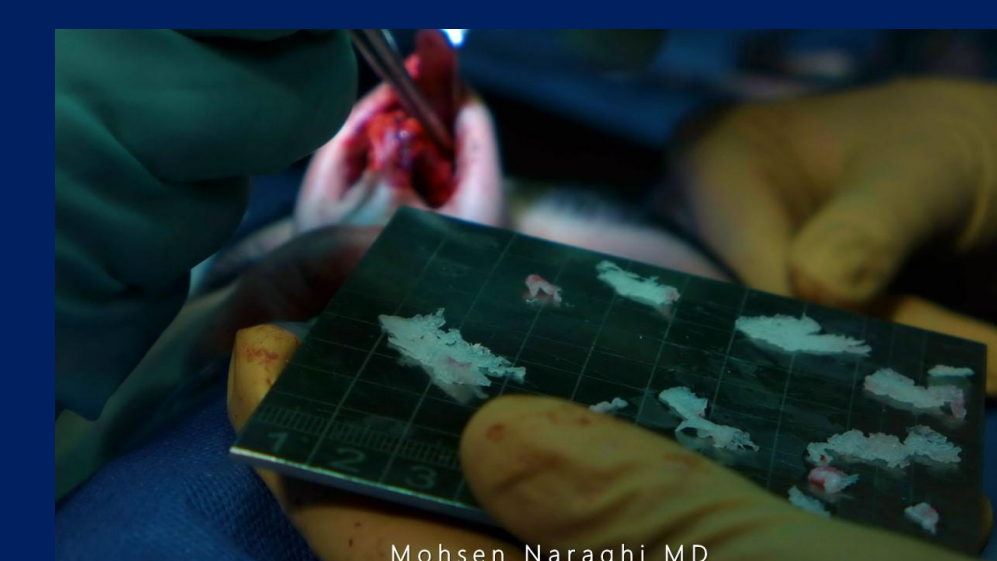
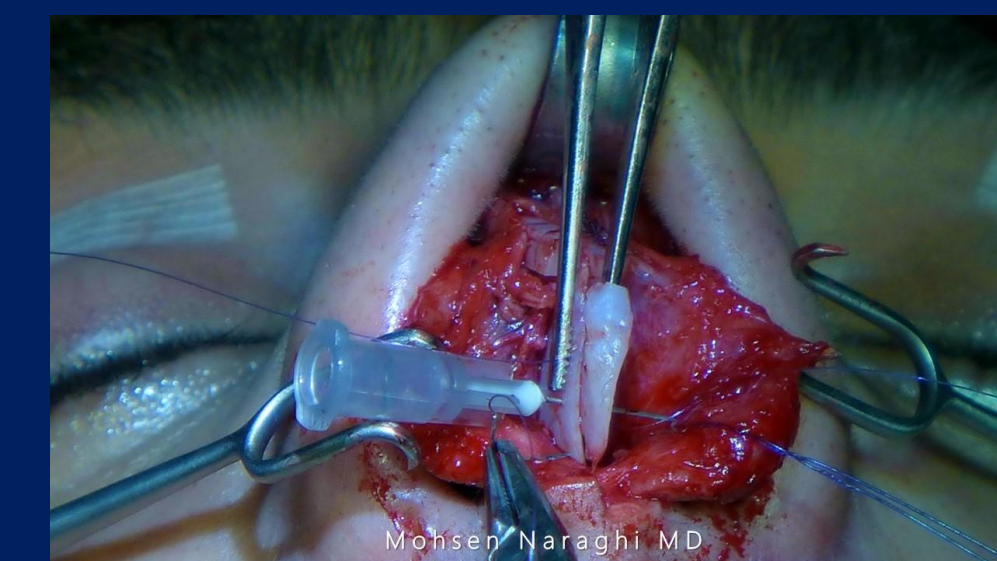
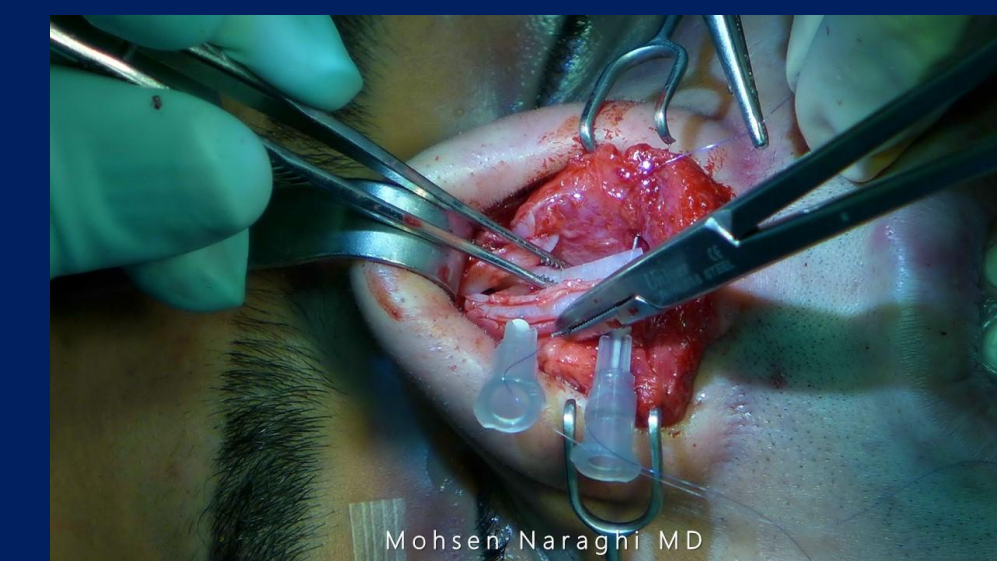
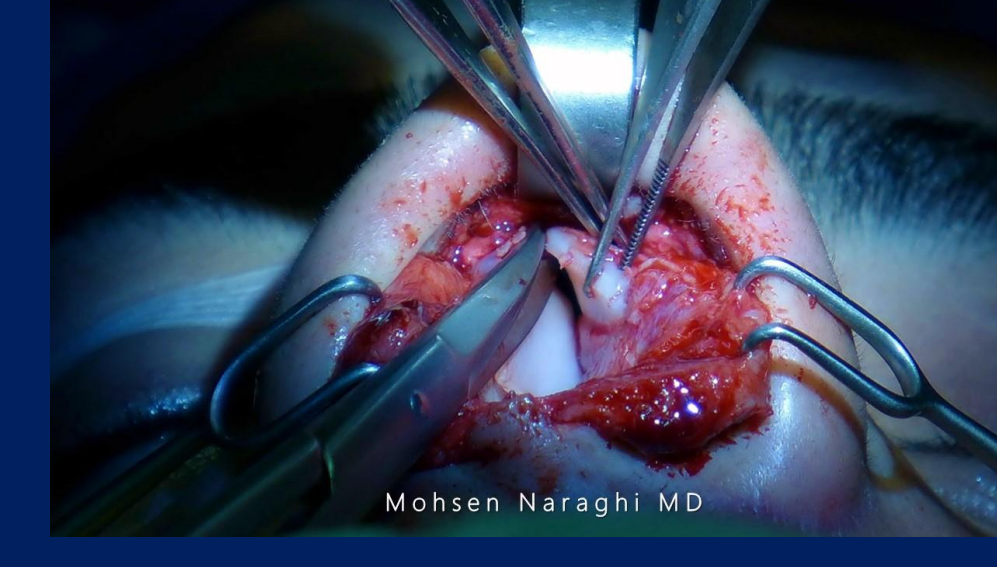
## Grafts



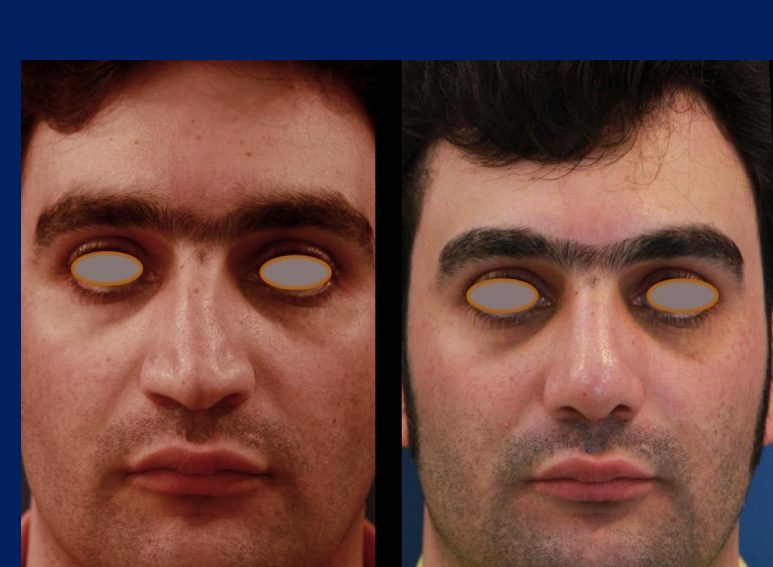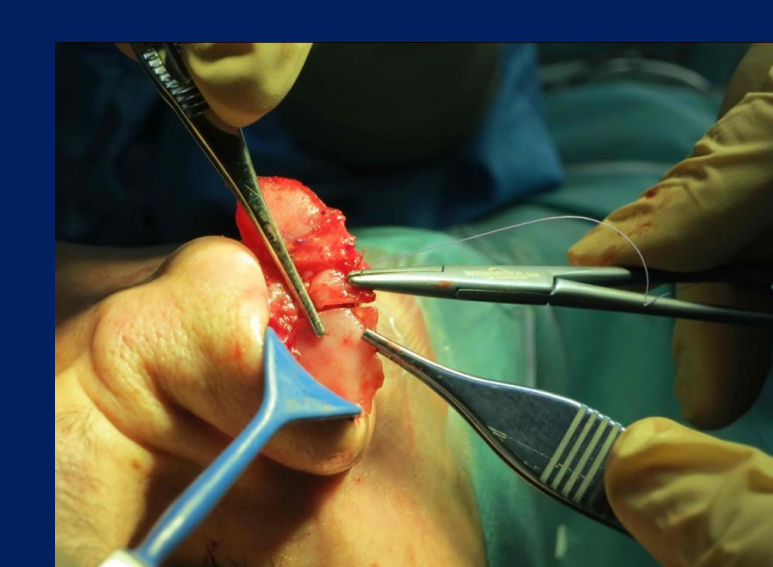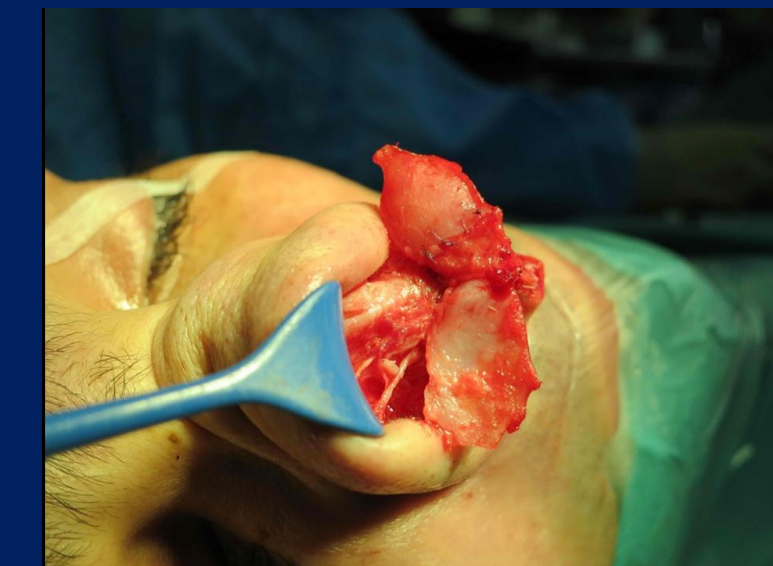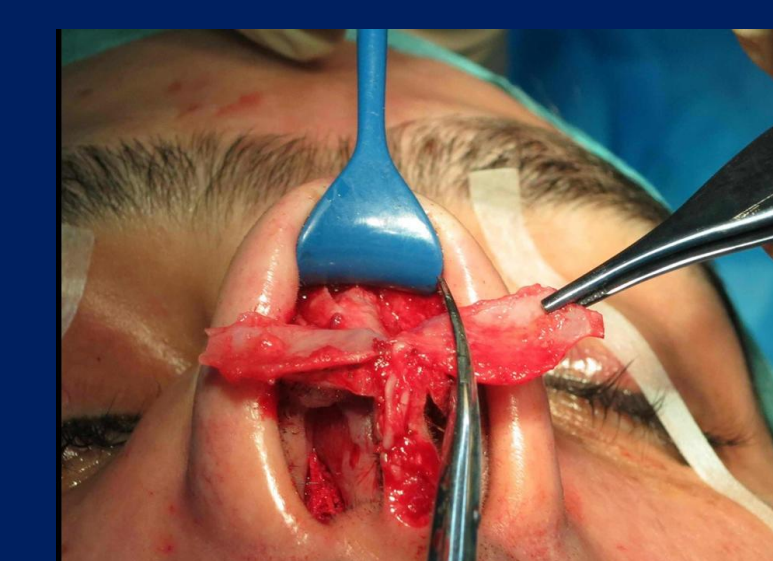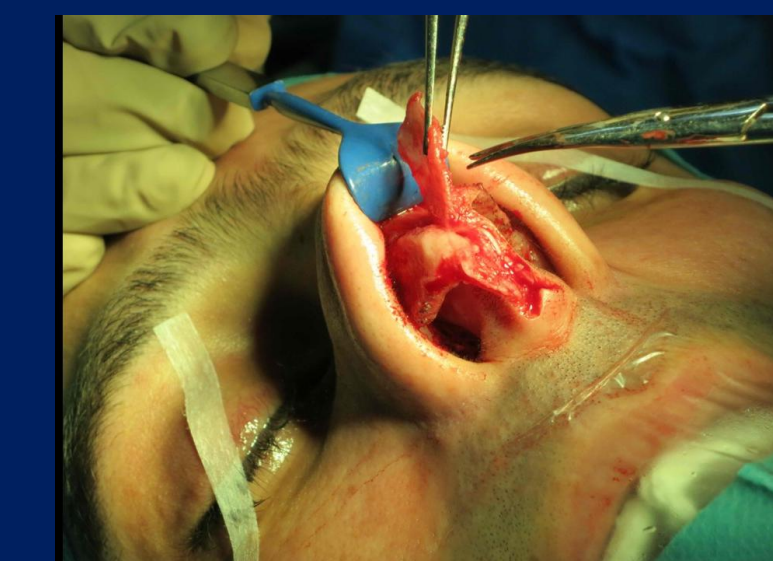
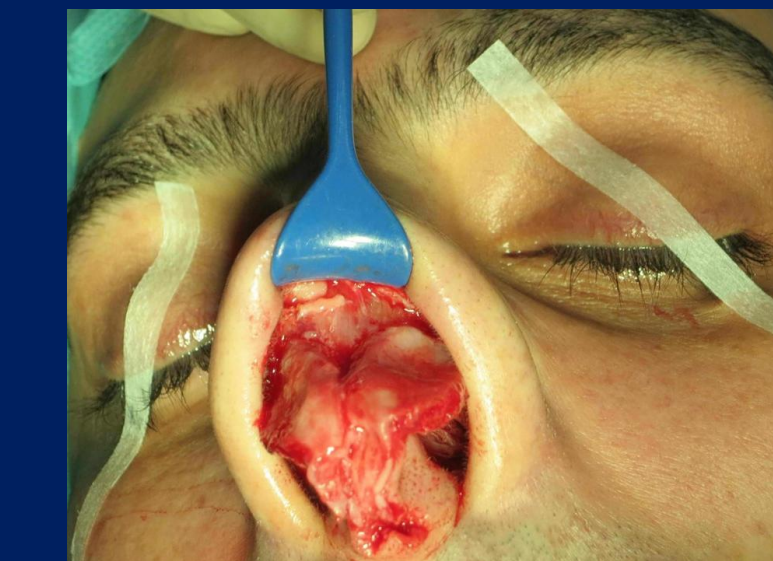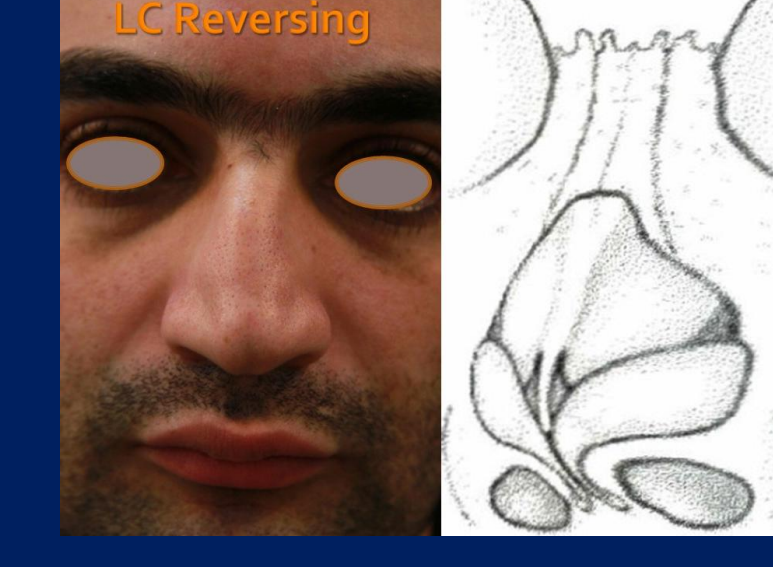
## Tip Adjustments



## Camouflage



## Asymmetries



## Pediatric

