

A Case of Burkitt Lymphoma with Concurrent HIV and CMV Viremia: A Diagnostic and Management Challenge

Elinor Barsh DO¹, Michele Basche MD², Dmitriy Scherbak DO¹
¹Sky Ridge Medical Center, Lone Tree, Colorado. ²Rocky Mountain Cancer Center, Lone Tree, Colorado.



Background

- Incidence of human immunodeficiency virus (HIV)-associated cancers dropped by 70% after the initiation of three-drug antiretroviral therapy in the mid-1990s. Among all HIV-associated cancers, Burkitt's lymphoma dropped to a lesser extent than other HIV-associated cancers.¹
- Burkitt's accounts for 40% of HIV-associated lymphomas, notably occurs in patients with a relatively normal CD4 count and cumulative HIV viremia.²
- Central nervous system (CNS) involvement occurs in 20 – 30% of HIV-associated Burkitt's patients.³
- 3-year overall survival (OS) of 70% in patients with HIV-associated Burkitt's.¹
- Cytomegalovirus (CMV) viremia is common in patients with advanced HIV (CD4 < 100), around 17 – 32%.⁴
- CMV encephalitis is a rare opportunistic infection, seen more commonly in advanced HIV patients with around 2 – 7%.⁵
- Mortality of CMV encephalitis is 40 – 60% with median OS of 3 months.⁶

Case Presentation

A 50-year-old male presented with night sweats, abdominal pain, and unintentional weight loss for the past 2-3 months. Two weeks prior to presentation, he had gone to the emergency room, where imaging showed diffuse retroperitoneal lymphadenopathy.

Past Medical History:

- Osteomyelitis of the ankle 3 years prior

Labs/imaging on admission:

- CT A/P: increased size/number of lymph node now 3 x 1.8 cm (previously 2.5 x 1.2 cm), borderline splenomegaly 13 cm, small bilateral pleural effusions
- Microcytic anemia (10.2), high nucleated red blood cells (0.08)

Hospital Course:

- Blood culture (+) salmonella due to salmonella enteritis
- Consult heme/onc: lymph node and bone marrow biopsy, lactate dehydrogenase, HIV, serum protein electrophoresis with immunofixation, urine protein electrophoresis, smear, CMV, hepatitis b and c virus, c-reactive protein, echocardiogram
- HIV-1 (+), CMV (+) seen in figure 2, and preliminary results of biopsies (+) Burkitt's seen in figure 3 → transferred to higher level of care hospital
- Rapid initiation of chemotherapy, CNS active treatment, and antiretroviral treatment (ART)

As of 4 months after his diagnosis, he has completed 5 cycles of dose-adjusted etoposide, prednisone, oncovin, cyclophosphamide, hydroxydaunorubicin, rituximab (DA-EPOCH-R) with C1, C3, C4 with high dose-methotrexate with a total of 6 planned. He received 2 doses of intrathecal medication, with methotrexate then cytarabine. He remains hospitalized with considerations of hospice.

Figures

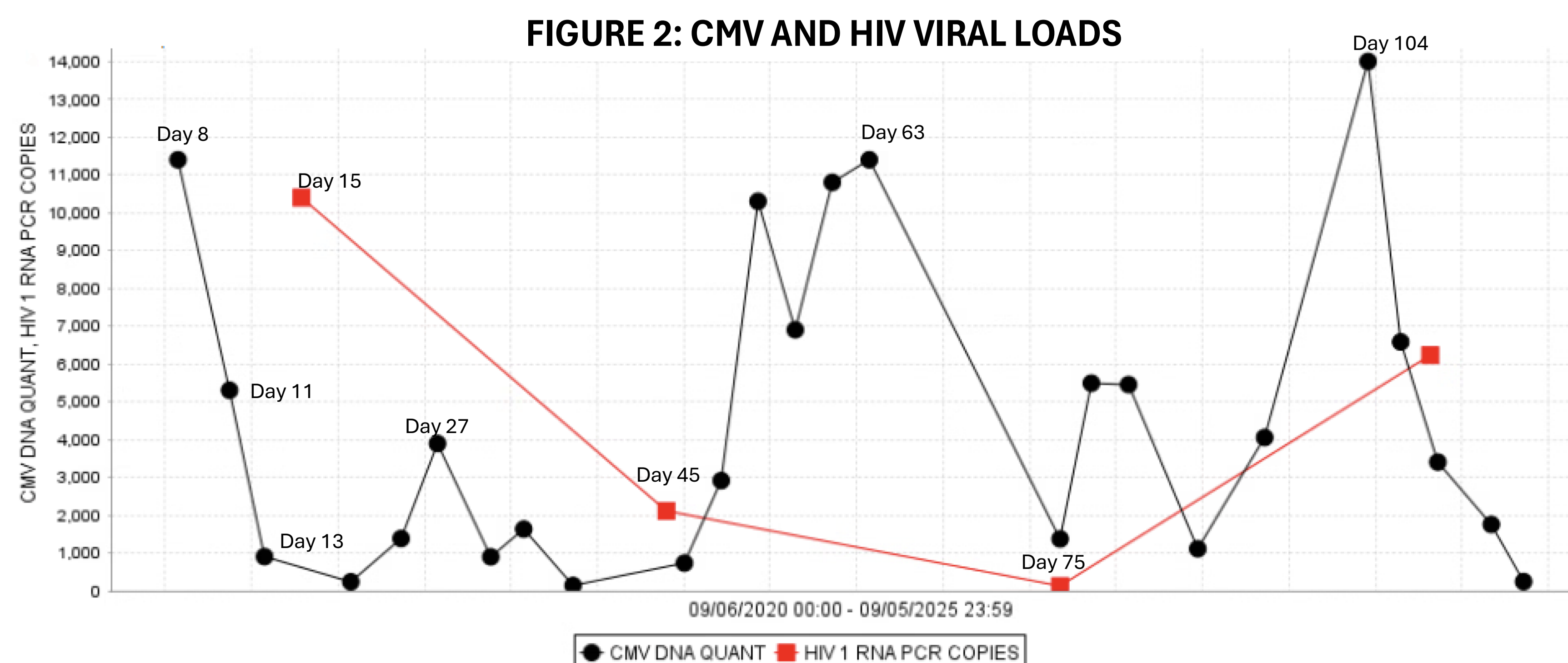
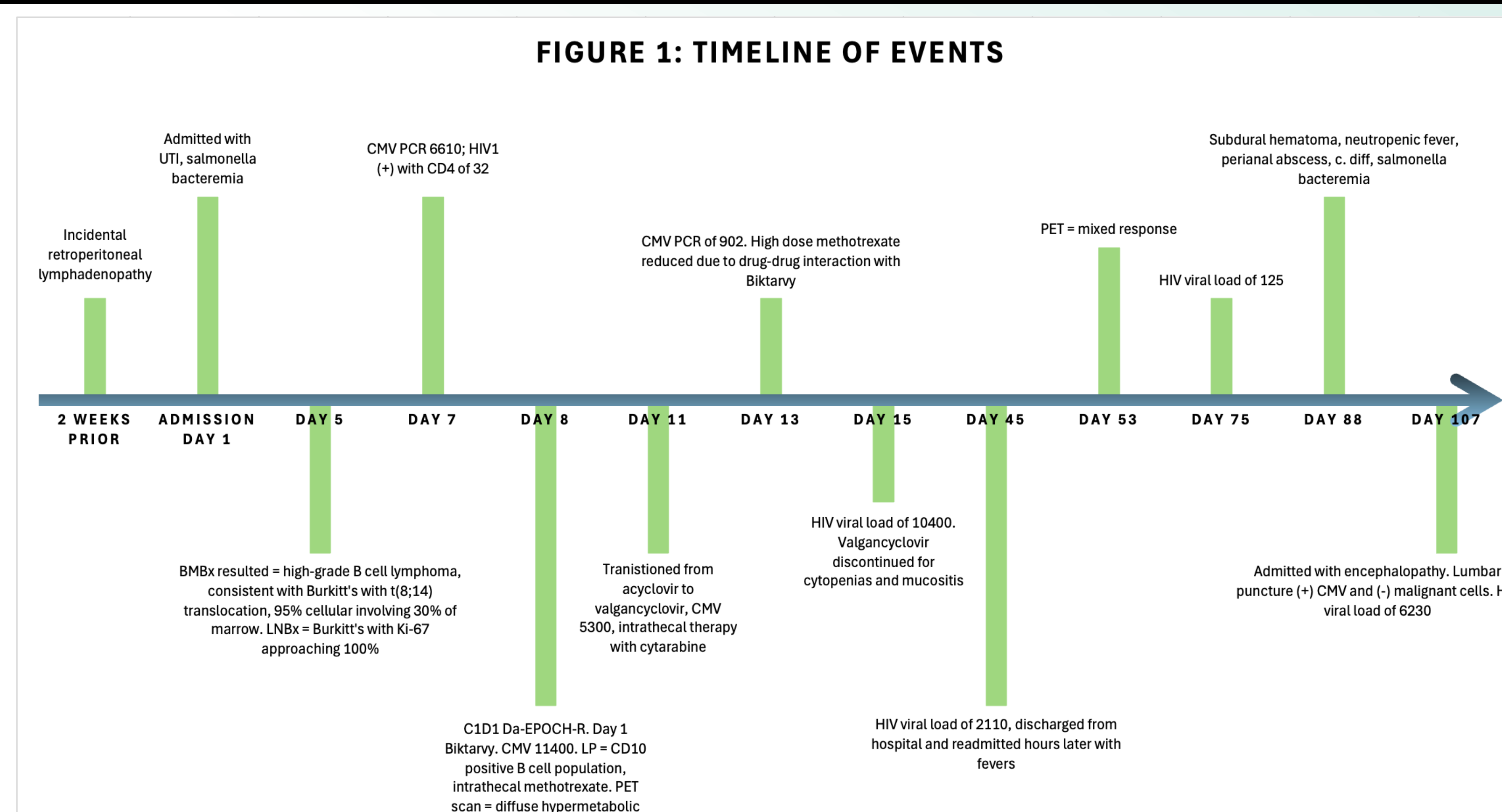
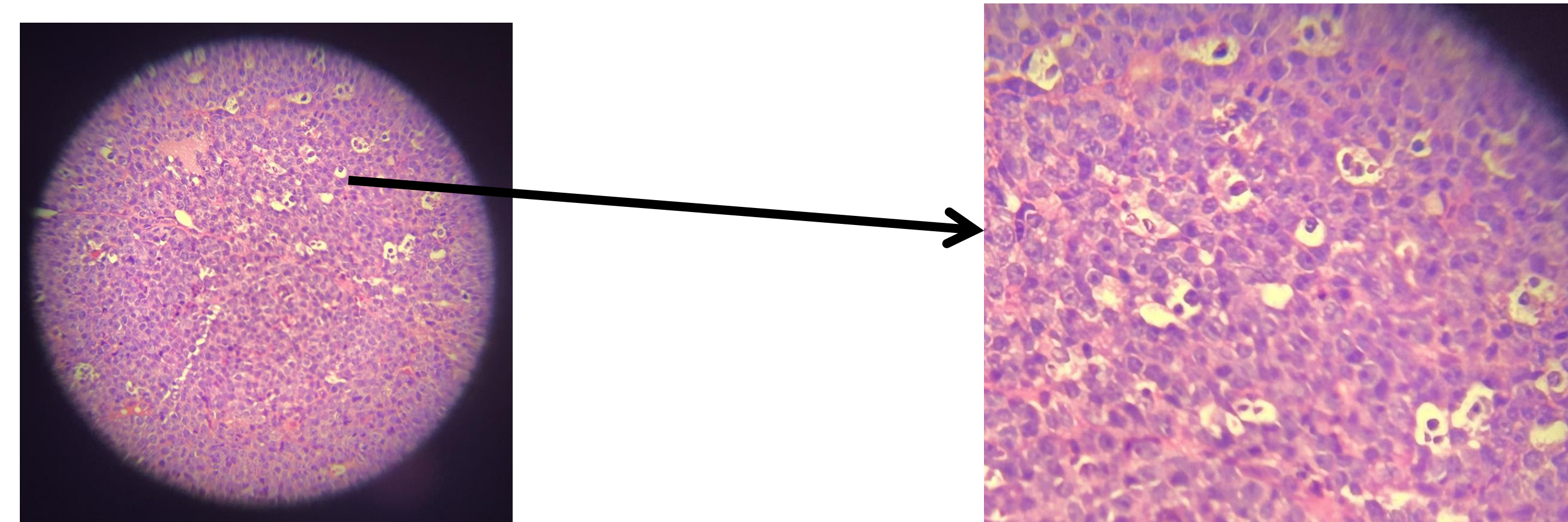


FIGURE 3: BIOPSY RESULTS, A STARRY SKY APPEARANCE



Discussion

- Atypical presentation: initially presented with constitutional symptoms and salmonella bacteremia, masking the underlying lymphoma.
- In immunocompromised patients, multiple processes can coexist. Anchoring on one diagnosis, as in this case with salmonella, CMV, and Burkitt's lymphoma, can delay recognition and treatment of the underlying malignancy.⁷
- Management complexity: Initiation of DA-EPOCH-R chemotherapy with CNS-directed therapy had to be carefully balanced against opportunistic infections, chemotoxicity, ART-related toxicities, and drug-drug interactions between ART and chemotherapy, as in this case, required a reduction of chemotherapy.
- Despite modern therapy, prognosis in HIV-associated Burkitt's with concurrent infections remains poor, underscoring the importance of early recognition and aggressive, multidisciplinary management.³
- For patients with HIV and cancer, initiation of ART should not be delayed due to the cancer diagnosis, and chemotherapy should not be delayed by ART initiation.⁷
- Lymphoma remains one of the lead causes of death in patients with HIV.⁸

Teaching points

- Always maintain suspicion for underlying immunodeficiency and malignancy in patients with systemic symptoms and lymphadenopathy.
- Opportunistic infections can obscure the diagnosis and complicate chemotherapy tolerance.
- Rapid coordination between oncology, infectious disease, and family support is critical to optimize outcomes.

References

1. Alderuccio JP, Olszewski AJ, Evens AM, et al. HIV-associated Burkitt lymphoma: outcomes from a US-UK collaborative analysis. *Blood Advances*. 2021;5(14):2852-2862. doi:10.1182/bloodadvances.2021004458
2. Evens AM, Danilov A, Jagadeesh D, et al. Burkitt lymphoma in the modern era: real-world outcomes and prognostication across 30 US cancer centers. *Blood*. 2021;137(3):374-386. doi:10.1182/blood.2020006926
3. Roschewski, Mark, Louis M. Staudt, and Wyndham H. Wilson. "Burkitt's lymphoma." *New England Journal of Medicine* 387.12 (2022): 1111-1122.
4. Levi LI, Sharma S, Schleiss MR, et al. Cytomegalovirus viremia and risk of disease progression and death in HIV-positive patients starting antiretroviral therapy. *AIDS* (02699370). 2022;36(9):1265-1272. doi:10.1097/QAD.0000000000003238
5. Anduze-Faris BM, Fillet A-M, Gozlan J, et al. Induction and maintenance therapy of cytomegalovirus central nervous system infection in HIV-infected patients. *AIDS*. 2000;14(5):517-524. Accessed September 7, 2025. <https://search.ebscohost.com/login.aspx?direct=true&site=eds-live&scope=site&db=edsuvi&AN=edsuvi.00002030.200003310.00007>
6. Lucas Júnior RM, Bogoni G, Reis Schneider GA, Castanheira de Souza NF, Carvalho MK, Vidal JE. AIDS-related cytomegalovirus encephalitis in the late ART era: A retrospective cohort study at a referral center in Brazil. *International journal of STD & AIDS*. 2023;34(4):229-235. doi:10.1177/09564624221124697
7. Carbone A, Vaccher E, Ghoghini A. Hematologic cancers in individuals infected by HIV. *Blood*. 2022;139(7):995-1012. doi:10.1182/blood.2020005469
8. Yarchoan R, Uldrick TS. HIV-Associated Cancers and Related Diseases. *The New England Journal of Medicine*. 2018;378(11):1029-1041. doi:10.1056/NEJMr1615896